

**UNIVERSIDADE FEDERAL DE JUIZ DE FORA
FACULDADE DE ODONTOLOGIA
PROGRAMA DE PÓS-GRADUAÇÃO EM CLÍNICA ODONTOLÓGICA**

LETÍCIA QUEIROZ MAUAD

**INFLUÊNCIA DE ARTEFATOS NA IDENTIFICAÇÃO DE *GAPS* EM
RESTAURAÇÕES INDIRETAS AVALIADAS EM IMAGENS DE TOMOGRAFIA
COMPUTADORIZADA DE FEIXE CÔNICO**

Juiz de Fora

2019

LETÍCIA QUEIROZ MAUAD

**INFLUÊNCIA DE ARTEFATOS NA IDENTIFICAÇÃO DE GAPS EM
RESTAURAÇÕES INDIRETAS AVALIADAS EM IMAGENS DE TOMOGRAFIA
COMPUTADORIZADA DE FEIXE CÔNICO**

Exame de defesa apresentado ao Programa de Pós-Graduação em Clínica Odontológica, da Faculdade de Odontologia da Universidade Federal de Juiz de Fora, como requisito parcial para obtenção do título de Mestre. Área de concentração em Clínica Odontológica.

Orientadora: Profa. Dra. Karina Lopes Devito

Juiz de Fora

2019

LETÍCIA QUEIROZ MAUAD

**INFLUÊNCIA DE ARTEFATOS NA IDENTIFICAÇÃO DE GAPS EM
RESTAURAÇÕES INDIRETAS AVALIADAS EM IMAGENS DE TOMOGRAFIA
COMPUTADORIZADA DE FEIXE CÔNICO**

Exame de defesa apresentado ao Programa de Pós-Graduação em Clínica Odontológica, da Faculdade de Odontologia da Universidade Federal de Juiz de Fora, como requisito parcial para obtenção do título de Mestre. Área de concentração em Clínica Odontológica.

Aprovada em: ___/___/___

BANCA EXAMINADORA

Profa. Dra. Karina Lopes Devito
Universidade Federal de Juiz de Fora

Profa. Dra. Laísa Araújo Cortines Laxe
Universidade Federal de Juiz de Fora

Prof. Dra. Janaina Araújo Dantas
União Metropolitana de Educação e Cultura

Ficha catalográfica elaborada através do programa de geração automática da Biblioteca Universitária da UFJF, com os dados fornecidos pelo(a) autor(a)

Mauad, Leticia Queiroz.

INFLUÊNCIA DE ARTEFATOS NA IDENTIFICAÇÃO DE GAPS EM RESTAURAÇÕES INDIRETAS AVALIADAS EM IMAGENS DE TOMOGRAFIA COMPUTADORIZADA DE FEIXE CÔNICO / Leticia Queiroz Mauad. -- 2019.

70 f. : il.

Orientadora: Karina Lopes Devito

Dissertação (mestrado acadêmico) - Universidade Federal de Juiz de Fora, Faculdade de Odontologia. Programa de Pós Graduação em Clínica Odontológica, 2019.

1. Artefatos. 2. restauração dentária permanente. 3. cerâmica. 4. restaurações metalocerâmicas. 5. adaptação marginal dentária. I. Devito, Karina Lopes, orient. II. Título.

AGRADECIMENTOS

Agradeço à **Universidade Federal de Juiz de Fora** e à **Faculdade de Odontologia**, pela oportunidade de ter concretizado o meu ideal de ser Mestre.

Ao **Programa de Pós-Graduação em Clínica Odontológica**, incluindo o corpo docente e coordenadores, pela contribuição intelectual a mim transmitida. À secretária do Programa de Pós-Graduação em Clínica Odontológica, Cláudio e Letícia, pela dedicação com a qual trabalham, sendo sempre muito solícitos e competentes.

À **Coordenação de Aperfeiçoamento de Pessoal de Nível Superior - CAPES** pelo auxílio financeiro recebido durante o Mestrado, possibilitando a realização da pesquisa.

À minha **orientadora, Prof^a. Dr^a. Karina Lopes Devito**, um grande exemplo de profissional e uma pessoa excepcional. Agradeço pela ótima convivência, pela oportunidade de aprender com sua experiência e por me transmitir seu conhecimento, tão valioso. Admiro sua paixão pela docência, profissionalismo e dedicação.

Aos professores que compuseram a banca examinadora da qualificação, o **Prof. Dr. Hugo Lemes Carlo** e **Prof^a. Dr^a. Francielle Silvestre Verner**, pelas brilhantes considerações que guiaram a confecção final deste trabalho.

Aos Professores participantes da banca de defesa **Prof^a. Dr^a Laísa Araújo Cortines Laxe**, **Prof^a. Dr^a Janaina Araújo Dantas** por gentilmente aceitarem o convite e pela disponibilidade em estarem presentes nesse dia, contribuindo para finalização desse trabalho.

Aos **funcionários da Faculdade de Odontologia** pela contribuição efetiva para que concluísse todas as atividades propostas durante o curso.

A todos os **pacientes** que depositaram sua confiança e permitiram meu aprendizado e crescimento pessoal e profissional.

À minha **família**: O apoio e incentivo de vocês faz com que os obstáculos pareçam menores e me ajudam a superar cada desafio. Vocês fizeram toda diferença na conclusão dessa importante etapa da minha vida.

À minha amiga de faculdade e da vida, **Alessiana**, que me incentivou a correr atrás desse sonho que hoje se concretiza.

A todos aqueles que, direta ou indiretamente contribuíram para minha formação, meu sincero agradecimento.

RESUMO

Em casos de reabilitação oral onde há grande perda de tecido dentário, coroas indiretas são indicadas e seu sucesso clínico depende de uma boa adaptação do material restaurador. Não existe uma ferramenta padrão para avaliar a adaptação marginal de restaurações, sendo indicado o exame clínico e radiográfico. Atualmente, imagens de tomografia computadorizada de feixe cônico (TCFC) são destacadas por permitir uma avaliação tridimensional com alta precisão. Porém, na presença de materiais de alta densidade há formação de artefatos. O objetivo no presente estudo foi avaliar a quantidade de artefatos gerados por diferentes materiais restauradores, bem como determinar a acurácia dos exames de TCFC e das radiografias periapicais na identificação de *gaps* marginais. Para isso, uma mandíbula contendo dentes restaurados com coroas metalocerâmicas e cerâmica pura, adequadamente adaptadas e com *gaps* de 0,30 e 0,50 mm, foram submetidas a exames de TCFC (com voxel de 0,25 e 0,30 mm) e radiografias periapicais. Os artefatos gerados pelas diferentes coroas foram quantificados e comparados pelo teste de Mann-Whitney. Além disso, cinco examinadores avaliaram a presença ou ausência de *gaps* nos diferentes exames por imagem. A acurácia dos exames testados foi determinada pela área sob a curva ROC e sua comparação foi realizada por meio do teste de Kruskal-Wallis. Os resultados demonstraram que não houve diferença significativa nos valores de artefatos entre os diferentes materiais restauradores e as diferentes resoluções das imagens de TCFC. Em relação à acurácia dos exames testados, a radiografia periapical e a TCFC com voxel de 0,25 mm, apresentaram o melhor desempenho para os *gaps* de menores dimensões (0,30 mm). Para *gaps* maiores (0,50 mm), todos os exames testados mostraram a mesma performance. Pode-se concluir que a radiografia periapical ainda apresenta o melhor custo-benefício para o diagnóstico de desconformidades em restaurações dentárias. Mas, apesar da TCFC obtida com voxel de 0,25 mm não ser o exame de primeira escolha para o diagnóstico de *gaps*, se o paciente já tiver essas imagens por outras indicações, ela poderia ser utilizada para avaliação de possíveis desconformidades marginais.

Palavras-chave: Artefatos, restauração dentária permanente, cerâmica, restaurações metalocerâmicas, adaptação marginal dentária.

ABSTRACT

In cases of oral rehabilitation in which there is great loss of dental tissue, indirect crowns are indicated and their clinical success depends on good adaptation of the restorative material. There is no standard tool for assessing marginal adaptation of restorations and clinical and radiographic examinations are indicated. Currently, cone beam computed tomography (CBCT) images are outstanding because they allow highly accurate three-dimensional evaluation. However, in the presence of high-density materials formation of artifacts occurs. The aim of the present study was to evaluate the quantity of artifacts generated by different restorative materials, and to determine the accuracy of CBCT scans and periapical radiographs in identifying peripheral gaps. For this purpose, a mandible containing teeth restored with metal-ceramic and all-ceramic crowns, properly adapted and with 0.30 and 0.50 mm gaps, underwent CBCT exams (with voxel sizes of 0.25 and 0.30 mm) and periapical radiographs. The artifacts generated by the different crowns were quantified and compared by the Mann-Whitney test. In addition, five examiners evaluated the presence or absence of gaps in different imaging exams. The accuracy of tests was determined by the area under the ROC curve and these values were compared by using the Kruskal-Wallis test. The results showed that there was no significant difference in artifact values between the different restorative materials and the different resolutions of CBCT images. Regarding the accuracy of the tests evaluated, periapical radiography and CBCT with voxel size 0.25 mm showed the best performance for smaller gaps (0.30 mm). For larger gaps (0.50 mm), all exams tested showed the same performance. It could be concluded that periapical radiography was still the most cost-beneficial method for the diagnosis of maladaptation in dental restorations. However, although CBCT with voxel size 0.25 mm is not the first choice for gap diagnosis, if the patient already has these images that were taken for other indications, they could be used to evaluate possible marginal mismatches.

Keywords: Artifacts, dental restoration permanent, ceramics, metal ceramic alloys, dental marginal adaptation.

LISTA DE ILUSTRAÇÕES

Quadro 1	Distribuição dos grupos de estudo	13
Figura 1	Mandíbula, com os dentes posicionados, revestida com cera utilidade para simular tecidos moles.	15
Figura 2	Mandíbula com os dentes devidamente posicionada para aquisição das imagens radiográfica.	16
Figura 3	Corte axial de TCFC ilustrando as quatro ROI posicionadas para quantificação dos artefatos.	17
Table 1	<i>Mean (standard deviation) quantification values of artifacts generated by the two types of crowns (metal-ceramic and all-ceramic) at the two CBCT image resolutions (0.25 mm and 0.30 mm).</i>	29
Table 2	<i>Comparison between metal-ceramic and all-ceramic crowns and among different CBCT image resolutions (voxel) on artifact production</i>	29
Figure 1	<i>CBCT axial section illustrating the four ROIs positioned for quantifying artifacts.</i>	42
Figure 2	<i>ROC curves showing comparison of accuracy of the three types of images for the diagnosis of 0.30 mm gap, evaluated by the five evaluators (a-e).</i>	42
Figure 3	<i>ROC curves showing comparison of accuracy of the three types of images for the diagnosis of 0.50 mm gap, evaluated by the five evaluators (a-e).</i>	43
Table 3	<i>Accuracy, defined by the area under the ROC curve, for the diagnosis of gaps obtained in different imaging exams.</i>	31
Figure 4	<i>ROC curves showing comparison of the accuracy of the three types of images for the diagnosis of gaps (0.30 mm and 0.50 mm), evaluated by the five evaluators (a-e).</i>	44
Figure 5	<i>Images of periapical and CBCT illustrating different gap sizes in metal-ceramic and all-ceramic crowns</i>	44

LISTA DE ABREVIATURAS E SIGLAS

<i>μm</i>	<i>Micrômetro</i>
<i>CAD</i>	<i>Computer-assisted Design</i>
<i>CAM</i>	<i>Computer-assisted Manufacture</i>
<i>CEP</i>	<i>Comitê de ética em pesquisa</i>
<i>cm</i>	<i>Centímetro</i>
<i>DICOM</i>	<i>Digital imaging and communications in medicine</i>
<i>DPR</i>	<i>Desvio padrão real</i>
<i>DPT</i>	<i>Desvio padrão teórico</i>
<i>Et al</i>	<i>Et alli</i>
<i>EUA</i>	<i>Estados Unidos da América</i>
<i>FO</i>	<i>Faculdade de Odontologia</i>
<i>FOV</i>	<i>Field of view</i>
<i>Kv</i>	<i>Quilovolt</i>
<i>mA</i>	<i>Miliampere</i>
<i>mm</i>	<i>Milímetro</i>
<i>N</i>	<i>Newton</i>
<i>ROI</i>	<i>Region of interest</i>
<i>s</i>	<i>Segundo</i>
<i>SPSS</i>	<i>Statistical Package for Social Sciences</i>
<i>TCFC</i>	<i>Tomografia computadorizada de feixe cônico</i>
<i>UFJF</i>	<i>Universidade Federal de Juiz de Fora</i>

SUMÁRIO

1 INTRODUÇÃO	9
2 PROPOSIÇÃO	11
3 MATERIAL E MÉTODOS	12
3.1 DESENHO DO ESTUDO.....	12
3.2 COMITÊ DE ÉTICA.....	12
3.3 PREPARO DA AMOSTRA.....	12
3.4 EXAMES POR IMAGEM.....	15
3.5 QUANTIFICAÇÃO DOS ARTEFATOS.....	16
3.6 AVALIAÇÃO DO <i>GAP</i> NAS COROAS.....	18
3.7 ANÁLISE DE DADOS.....	18
3.7.1 Análise objetiva	19
3.7.2 Análise subjetiva	19
4 ARTIGO	20
6 CONSIDERAÇÕES FINAIS	44
REFERÊNCIAS	45
ANEXOS	50

1 INTRODUÇÃO

Quando se trata de reabilitação oral, em casos de grande perda de tecido dentário, as técnicas restauradoras indiretas são as mais indicadas, uma vez que permitem restaurar a coroa com materiais mais resistentes, devolvendo não só a estética, como também, a função mastigatória ao paciente. Essas coroas protéticas podem ser compostas por ligas metálicas (ouro, paládio, prata, cobalto, cobre, níquel ou alumínio) ou por materiais livres de metal, como fibras de vidro e carbono, materiais cerâmicos puros ou reforçados por zircônia (CHABOUIS, FAUGERON, ATTAL, 2013; ROZYLO-KALINOWSKA et al., 2014).

O sucesso clínico das restaurações depende diretamente de uma boa adaptação marginal. A presença de fendas ou desadaptações, também chamadas de *gaps*, representa um problema clínico relevante, estando diretamente associada à fratura, à perda de retenção devido à dissolução do agente cimentante e ao surgimento de lesões cariosas secundárias, uma vez que favorece a microinfiltração de bactérias e seus subprodutos, aumentando a susceptibilidade à inflamação da polpa vital e pigmentação marginal (BORBA et al., 2013; RICCITIELLO et al., 2018).

Diferentes técnicas e ferramentas podem ser utilizadas para avaliar a adaptação marginal de restaurações indiretas (BORBA et al., 2013). O exame clínico com auxílio da sonda exploradora pode auxiliar na identificação de falhas e desadaptações marginais, porém, para uma melhor avaliação das regiões interproximais, os exames por imagem devem ser utilizados. As radiografias interproximais e periapicais auxiliam o cirurgião dentista no diagnóstico de lesões cariosas primárias e secundárias e identificação de diversas falhas restauradoras (KAMBUROGLU et al., 2012; MURAT et al., 2013; WENZEL et al., 2013; ABU EL-ELA, FARID, MOSTAFA, 2016; VEDPATHAK et al., 2016). No entanto, não podemos deixar de considerar as limitações dos exames bidimensionais, como por exemplo, a sobreposição de planos, que muitas vezes, pode prejudicar a visualização de estruturas importantes.

Apesar da tomografia computadorizada de feixe cônico (TCFC) não ser o exame por imagem de escolha para a avaliação de restaurações dentárias, especialmente em função da maior dose de radiação quando comparada às radiografias convencionais, a TCFC vem sendo amplamente utilizada na

Odontologia devido ao seu alto potencial de diagnóstico, além de possibilitar uma avaliação tridimensional das imagens evitando a sobreposição de estruturas (KUUSISTO et al., 2015; OMAR, ABDELSALAM, HAMED, 2016; VEDPATHAK et al., 2016; FREITAS, VASCONCELOS, NOUJEIM, 2019; PARK et al., 2019). No entanto, em avaliações pós-tratamentos reabilitadores, a qualidade das imagens de TCFC pode ser prejudicada devido a formação de artefatos gerados na presença de materiais de alta densidade utilizados em restaurações, coroas, implantes e próteses, podendo comprometer o diagnóstico (GONG et al., 2013; SIMÕES e CAMPOS, 2013; KULCZYK et al., 2014; ROZYLO-KALINOWSKA et al., 2014; GAALAAS et al., 2016; OMAR, ABDELSALAM, HAMED, 2016; FREITAS, VASCONCELOS, NOUJEIM, 2019; KUUSISTO et al., 2019).

Sabendo da importância da avaliação cuidadosa da adaptação de restaurações indiretas e dos exames acurados de imagens disponíveis atualmente, o presente estudo teve como objetivo avaliar a quantidade de artefatos gerados por diferentes materiais restauradores, bem como determinar a acurácia dos exames de TCFC e das radiografias periapicais digitais na identificação de *gaps* marginais.

2 PROPOSIÇÃO

Avaliar a influência de artefatos na identificação de *gaps* marginais em restaurações indiretas por meio da:

- Quantificação dos artefatos em exames de TCFC de diferentes resoluções;
- Determinação da acurácia dos exames de TCFC e das radiografias periapicais digitais no diagnóstico desses *gaps*.

3 MATERIAL E MÉTODOS

3.1 DESENHO DO ESTUDO

Trata-se de um estudo experimental analítico *ex vivo*.

3.2 COMITÊ DE ÉTICA

Este estudo foi aprovado pelo Comitê de Ética em Pesquisa da Universidade Federal de Juiz de Fora (CEP/UFJF, Juiz de Fora, Minas Gerais, Brasil), sob o parecer nº. 2.435.835/2017 (ANEXO A).

3.3 PREPARO DA AMOSTRA

Para o desenvolvimento da pesquisa foi utilizada uma mandíbula edêntula com alvéolos, confeccionada em bário (Nacional Ossos, Jaú, SP, Brasil), que simula as características da densidade óssea radiográfica humana. Para inserção na mandíbula, foram adquiridos junto ao Biobanco de Dentes da Faculdade de Odontologia da UFJF, 32 dentes inferiores hígidos (31 molares e um pré-molar), sendo que um molar e o pré-molar foram utilizados apenas para permitir o contato proximal com os dentes da amostra. Os trinta molares selecionados para o estudo deveriam apresentar dimensões vestibulo-lingual e méso-distal semelhantes ou com uma variação máxima de 10%.

Trinta molares foram submetidos a preparos para coroa total, usando um micromotor de alta rotação (Dabi Atlante, Ribeirão Preto, SP, Brasil), ponta montada de diamante e broca carbide (KG Sorensen, Cotia, SP, Brasil). Os preparos foram padronizados com auxílio de um modelo de silicone de condensação (Coltene, Altstätten, Suíça). Com paredes expulsivas (aproximadamente 6°) para facilitar a acomodação da peça protética, desgastes oclusais de 2 mm e axiais de 1,5 mm, foram realizados com ponta montada de diamante, tronco cônica de extremidade arredondada e granulação média (nº 4138). O acabamento foi realizado com broca carbide (nº 283). O término do preparo em chanfro e todos os ângulos internos foram arredondados (PEDROCHE et al., 2016). Os dentes foram preparados por um único

cirurgião dentista, especialista em Dentística, e enviados para um laboratório protético para confecção das restaurações.

Os 30 dentes foram divididos aleatoriamente em dois grupos: Grupo Cerâmica Pura: 15 dentes restaurados com coroas totais, sendo coping em zircônia Ceramill ZI White 71L (Amman Girschbach, Koblach, Áustria), coberto pela cerâmica feldspática (Kuraray Noritake Dental, Tóquio, Japão), de forma que 10 dentes apresentavam desadaptações marginais (0,3 e 0,5 mm) e cinco dentes apresentavam adequada adaptação marginal; Grupo Metalocerâmica: 15 dentes restaurados com coroas totais metalocerâmicas compostas pela liga metálica de níquel-cromo Dan Ceramalloy (Nihon Shika Kinzoku, Osaka, Japão), coberto pela mesma cerâmica feldspática utilizada no Grupo Cerâmica Pura. Da mesma forma, 10 dentes apresentavam *gap* (0,3 e 0,5 mm) e cinco dentes possuíam coroas bem adaptadas. A distribuição dos grupos e o respectivo número da amostra encontram-se apresentados no Quadro 1.

Quadro 1 - Distribuição dos grupos de estudo

	Metalocerâmica	Cerâmica Pura	TOTAL
<i>Gap</i> 0,3 mm	n = 5	n = 5	n = 10
<i>Gap</i> 0,5 mm	n = 5	n = 5	n = 10
Grupo controle*	n = 5	n = 5	n = 10
TOTAL	n = 15	n = 15	n = 30

*Coroa adaptada (sem *gap*)

No CAD-CAM (Ceramill Motion, Amann Girschbach, Koblach, Áustria), foram fresados os copings em zircônia e os copings em cera Ceramill Wax Grey 71L (Amann Girschbach, Koblach, Áustria) que posteriormente foram fundidos em metal. Nenhum coping recebeu ajuste nem desgaste em suas faces internas. Os *gaps* foram feitos nas faces mesiais ou distais, aleatoriamente, programados pelo equipamento protético CAD-CAM. Não foram simulados *gaps* em faces vestibular e lingual, uma vez que desadaptações nessas faces podem ser diagnosticadas mais facilmente durante o exame clínico. Alguns autores consideram discrepâncias marginais entre 50 e 150 μ m aceitáveis clinicamente (REICH et al., 2008; HABIB et al., 2017). No presente estudo, os *gaps* marginais foram simulados em dois

tamanhos: 300 μm (0,3 mm) e 500 μm (0,5 mm), uma vez que se pretende identificar *gaps* que sejam prejudiciais à integridade da restauração, passíveis de infiltração. Numa segunda etapa, os coppings receberam a cobertura da cerâmica feldspática, de forma cuidadosa para não mascarar a desadaptação marginal simulada na etapa anterior.

As coroas não foram cimentadas, apenas acomodadas, para que o cimento não mascarasse as possíveis desadaptações e os *gaps* simulados. Para acomodação da coroa, foi padronizada uma força de encaixe de 50 N, realizada na superfície oclusal da coroa, perpendicularmente ao longo eixo do dente (RICCITIELLO et al., 2018).

Os dentes restaurados foram inseridos nos alvéolos e fixados com auxílio de cera utilidade (Technew, Rio de Janeiro, Brasil). Cada dente restaurado foi posicionado entre dois dentes hígidos, um pré-molar na posição mesial e um molar localizado na distal para simular o ponto de contato. Os dentes hígidos foram sempre os mesmos e colocados na mesma posição, alterando-se apenas o dente restaurado. Para cada dente restaurado, foi realizada aquisição de radiografia periapical digital e exames de TCFC com variação no tamanho do voxel.

A densidade tomográfica da gengiva e do tecido mole facial foi simulada com auxílio de cera utilidade, posicionada na face vestibular e lingual da mandíbula com espessura de 15 mm (Figura 1) (SCHROPP et al., 2012; NEVES et al., 2014).

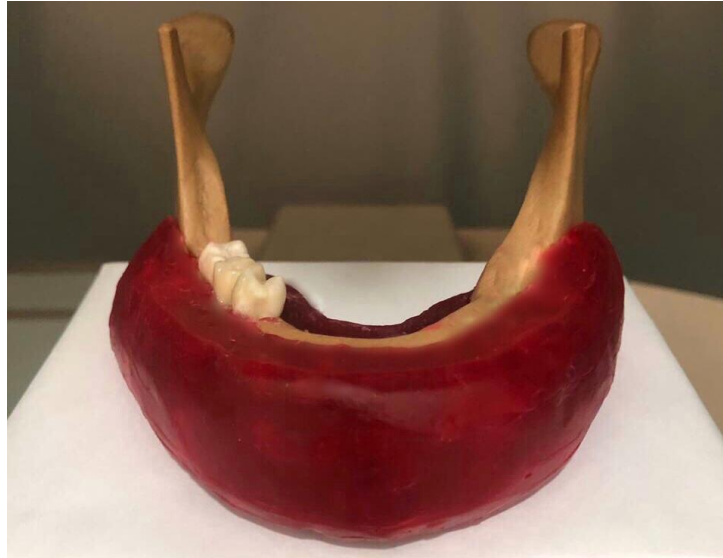

Figura 1 – Mandíbula, com os dentes posicionados, revestida com cera utilidade para simular tecidos moles.

Fonte: O autor

3.4 EXAMES POR IMAGEM

A mandíbula com os dentes devidamente posicionados foi submetida a exames de TCFC na Clínica de Radiologia Odontológica da FO/UFJF (Juiz de Fora, Minas Gerais, Brasil), utilizando com o aparelho I-Cat[®] *Next Generation* (Imaging Sciences International, Hatfield, Pensilvânia, EUA), com o seguinte protocolo de aquisição: 120 kV, 8 mA e 360° de rotação, FOV (*field of view*) de 5 x 13 cm. Foram utilizados dois tamanhos de voxel: 0,25 mm e 0,30 mm.

Também foram realizadas radiografias periapicais dos dentes, utilizando a técnica do paralelismo (Figura 2). Os dentes foram posicionados na mandíbula com o longo eixo perpendicular ao plano oclusal, a película acomodada na face lingual e paralelamente aos dentes, de forma que o feixe de raios X incidisse perpendicularmente às superfícies proximais. As imagens foram feitas com o aparelho de radiografia periapical Heliodont Plus[®] (Sirona, Bensheim, Germany) e o sistema digital direto VistaScan (Durr Dental, Bietigheim-Bissingen, Alemanha) com o seguinte protocolo: tempo de exposição de 0,32 s, distância foco-filme (DFF) de 10cm, 7 mA DC e 60-70 kVp.



Figura 2 - Mandíbula com os dentes devidamente posicionada para aquisição das imagens radiográficas
Fonte: O autor.

Para cada dente restaurado foi realizada uma aquisição radiográfica e duas aquisições tomográficas com diferentes resoluções, sendo uma com voxel de 0,25 mm e outra com voxel de 0,30 mm.

3.5 QUANTIFICAÇÃO DOS ARTEFATOS

Após aquisição das imagens tomográficas, as mesmas foram armazenadas descomprimidas em formato DICOM (*Digital Imaging and Communications in Medicine*). Foi selecionado o corte axial mais cervical que continha toda a restauração. Esses cortes foram definidos individualmente para cada dente e avaliados no software ImageJ (U. S. National Institutes of Health, Bethesda, Maryland, EUA). Foram selecionadas quatro ROIs (*region of interest*) retangulares de dimensões padronizadas (8 x 3 mm). Essas ROIs abrangeram as regiões mesial, distal, vestibular e lingual do dente a ser analisado (Figura 3).

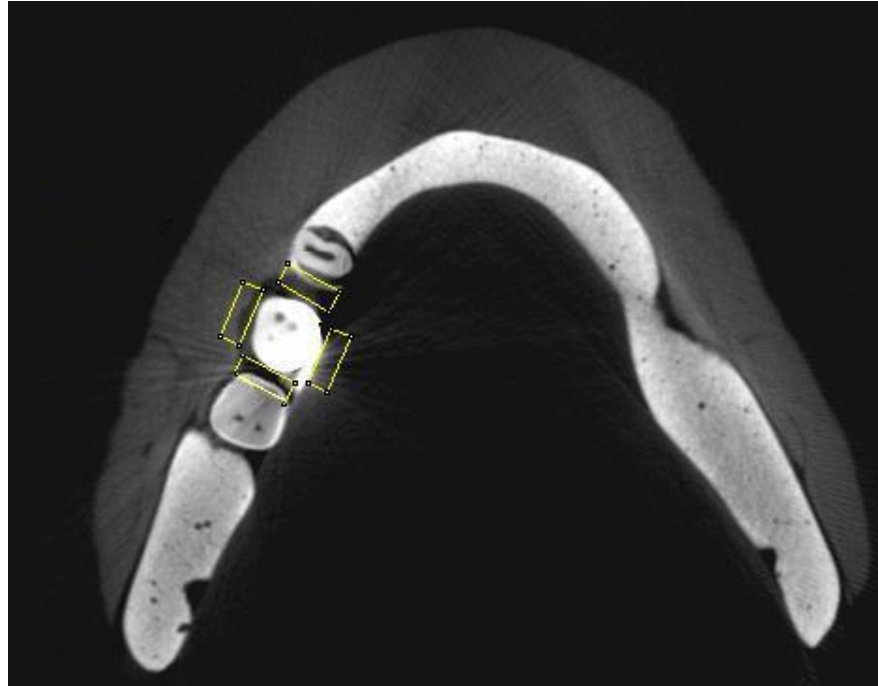


Figura 3 - Corte axial de TCFC ilustrando as quatro ROI posicionadas para quantificação dos artefatos.

Fonte: O autor.

Para cada ROI selecionada, foram quantificados os artefatos presentes baseando-se na metodologia de Pauwels et al. (2013). Ainda no *software* ImageJ, por meio das ferramentas “*Analyze – Histogram*”, foram determinados os valores mínimo e máximo de tons de cinza para calcular o desvio padrão real (DPR). O cálculo matemático do DPR foi realizado no programa Excel, versão 2010 (Windows XP, Microsoft, EUA).

Utilizando-se uma escala de 16 bits (65.536 valores de cinza), já que as imagens geradas a partir do tomógrafo utilizado nesse estudo possuem essa característica, foi determinado o desvio padrão teórico máximo (DPT), cujo valor é a metade dos valores de cinza de uma imagem de 16 bits, ou seja, 32.768. Foi considerado o valor de 32.768 tons de cinza, uma vez que metade dos voxels de uma imagem é preto e metade é branco, assim o DPT máximo deverá ser exatamente a metade dos valores de cinza de uma determinada imagem. Posteriormente o DPR foi convertido em uma porcentagem do DPT máximo, onde valores mais elevados indicam artefatos mais pronunciados. O cálculo foi realizado da seguinte forma:

$$(\text{DPR} / \text{DPT máximo}) \times 100 = \text{quantificação de artefato}$$

O artefato referente a cada dente restaurado foi definido como uma média das mensurações das quatro ROIs. A seleção dos cortes axiais, bem como a quantificação dos artefatos foi realizada por um único examinador experiente em imagens de TCFC. Para mensurar a reprodutibilidade do método, 30% dos exames foram avaliados em dois momentos distintos, com intervalo de duas semanas entre eles, para o cálculo da concordância intraobservador.

3.6 AVALIAÇÃO DO GAP NAS COROAS

Cinco radiologistas cegos (que desconheciam a distribuição dos dentes nos dois grupos) avaliaram as imagens tomográficas e radiográficas. As avaliações foram feitas no mesmo computador ASUSTek (Taipé, Taiwan), processador Intel® Core™ i5-4440 com monitor Samsung (Seul, Coreia do Sul) 18,5 polegadas, resolução da tela 1366 x 768, profundidade de cor 32 bits, software Windows 7 Ultimate, em um ambiente com baixa luminosidade. As imagens radiográficas foram organizadas aleatoriamente em Power Point (Microsoft Store, EUA) e salvos em PDF para avaliação.

Os examinadores avaliaram independentemente as superfícies proximais (mesial e distal) de cada dente, quanto à presença de *gaps* nos dentes restaurados. Foi utilizada uma escala de cinco escores: 1- *Gap* definitivamente ausente; 2- *Gap* provavelmente ausente; 3- incerteza sobre ausência ou presença de *gap*; 4- *gap* provavelmente presente; 5- *gap* definitivamente presente.

Para mensurar a reprodutibilidade do método, todos os exames foram avaliados em dois momentos distintos, com intervalo de duas semanas entre eles, para o cálculo da concordância intra e interobservador.

3.7 ANÁLISE DE DADOS

Para realizar a análise de dados foi utilizado o programa SPSS (*Statistical Package for the Social Sciences*, versão 22.0, Chicago, EUA), com nível de significância de 5% ($p \leq 0,05$).

3.7.1 Análise Objetiva

Para verificar a concordância intraexaminador nos valores de artefatos foi aplicado o coeficiente de correlação intraclassa (ICC). Como os dados não apresentaram distribuição normal pelo teste de Shapiro-Wilk ($p < 0,05$), foi aplicado o teste não paramétrico de Mann-Whitney para comparação entre as coroas (metalocerâmica e cerâmica pura) e as resoluções dos exames de TCFC (0,25 mm e 0,30 mm).

3.7.2 Análise Subjetiva

Para o cálculo da concordância intra e interobservador foi utilizado o coeficiente Kappa. Para verificar a acurácia dos exames testados (TCFC 0,25 mm de voxel, TCFC 0,30 mm de voxel e radiografia periapical) para o diagnóstico dos *gaps* em restaurações indiretas foi determinada a área sob a curva ROC para cada avaliador. A comparação entre os exames testados foi realizada por meio do teste de Kruskal-Wallis e Student-Newman-Keuls.

4 ARTIGO

O artigo a seguir está apresentado nas normas do periódico *Clinical Oral Investigations*, classificado no Qualis da CAPES (Coordenação de Aperfeiçoamento de Pessoal de Nível Superior), na Área de Avaliação de Odontologia, como A1 (ANEXO B). O comprovante de submissão do artigo ao periódico está apresentado no ANEXO C.

INFLUENCE OF ARTIFACTS ON IDENTIFYING GAPS IN INDIRECT RESTORATIONS EVALUATED IN CONE BEAM COMPUTED TOMOGRAPHY IMAGES

Authors:

Letícia Queiroz Mauad*

Karolina Aparecida Castilho Fardim*

Alessiana Helena Machado*

Paulo Victor Teixeira Doriguêto*

Daniela de Almeida*

Karina Lopes Devito**

Authors' affiliations:

* Postgraduate Program in Dentistry, School of Dentistry, Federal University of Juiz de Fora, Juiz de Fora, Minas Gerais, Brazil.

** Department of Dental Clinic, School of Dentistry, Federal University of Juiz de Fora, Juiz de Fora, Minas Gerais, Brazil.

Corresponding author:

Karina Lopes Devito

Department of Dental Clinic, School of Dentistry, Federal University of Juiz de Fora, Campus Universitário, s/n.

CEP: 36036-900 - Juiz de Fora, MG, Brazil

E-mail: karina.devito@ufff.edu.br

Acknowledgments:

This study was financed by the Coordenação de Aperfeiçoamento de Pessoal de Nível Superior - Brazil (CAPES) - Finance Code 001.

INFLUENCE OF ARTIFACTS ON IDENTIFYING GAPS IN INDIRECT RESTORATIONS EVALUATED IN CONE BEAM COMPUTED TOMOGRAPHY IMAGES

Abstract

Objectives: To evaluate the quantity of artifacts generated by different restorative materials, and to determine the accuracy of CBCT scans and periapical radiographs in identifying peripheral gaps.

Material and Methods: A mandible containing teeth restored with metal-ceramic and all-ceramic crowns, properly adapted and with 0.30- and 0.50-mm gaps, underwent CBCT exams (with voxel sizes of 0.25 and 0.30 mm) and periapical radiographs. The artifacts generated by the different crowns were quantified and compared by the Mann-Whitney test. In addition, five examiners evaluated the presence or absence of gaps in different imaging exams. The accuracy of tests was determined by the area under the ROC curve and these values were compared by using the Kruskal-Wallis test.

Results: There was no significant difference in artifact values between the different restorative materials and the different resolutions of CBCT images. Regarding the accuracy of the tests evaluated, periapical radiography and CBCT with voxel size 0.25 mm showed the best performance for smaller gaps (0.30 mm). For larger gaps (0.50 mm), all exams tested showed the same performance.

Conclusions: Periapical radiography was still the most cost-beneficial method for the diagnosis of maladaptation in dental restorations. However, although CBCT with voxel size 0.25 mm is not the first choice for gap diagnosis, if the patient already has these images that were taken for other indications, they could be used to evaluate possible marginal mismatches.

Clinical relevance: The results of this study will allow practitioners to know the indications and limitations of CBCT images for the diagnosis of gaps in indirect restorations, including in addition to quantifying tomographic artifacts, a verification of the accuracy of the clinical diagnosis of these gaps.

Keywords

Cone beam computed tomography, artifacts, dental restoration, ceramics, metal ceramic alloys, dental marginal adaptation.

Introduction

As far as oral rehabilitation is concerned, in cases of great loss of dental tissue, indirect restorative techniques are the most suitable, since they allow the crown to be restored with more resistant materials, thereby returning not only the patient's aesthetic appearance, but also the chewing function of the teeth. These prosthetic crowns may be composed of metal alloys (gold, palladium, silver, cobalt, copper, nickel, or aluminum) or metal-free materials such as glass and carbon fibers, ceramic materials that are pure or zirconia-reinforced [1,2]

The clinical success of restorations depends directly on good peripheral adaptation. The presence of cracks or mismatches, also called gaps, represents a relevant clinical problem that is directly associated with fracture, loss of retention due to dissolution of the cementing agent and the appearance of secondary carious lesions, since it favors the microleakage of bacteria and their byproducts, increasing the susceptibility to vital pulp inflammation and marginal pigmentation [3,4]

Different techniques and tools can be used to assess marginal adaptation of indirect restorations [3]. Clinical examination with the aid of the exploratory probe may help to identify faults and marginal mismatches; however, for a better evaluation of interproximal regions, imaging should be used. Interproximal and periapical radiographs assist the dental surgeon in diagnosing primary and secondary carious lesions and identifying several types of restorative failures [5-9]. However, we cannot fail to consider the limitations of two-dimensional examinations, such as overlapping planes that can frequently impair visualization of the important structures.

Although cone-beam computed tomography (CBCT) is not the imaging exam of choice for dental restorations, especially due to the higher radiation dose when compared with conventional radiographs, CBCT has been widely used in dentistry due to its high diagnostic potential, in addition to allowing a three-dimensional evaluation of the images by avoiding overlapping structures [9-13]. However, in evaluations after rehabilitative treatments, the quality of CBCT images may be impaired due to the formation of artifacts generated in the presence of high-density materials used in restorations, crowns, implants and prostheses, which may compromise the diagnosis [2,10-12,14-17].

Being aware of the importance of careful assessment of the adaptation of indirect restorations and accurate imaging exams available at present, this study

aimed to assess the quantity of artifacts generated by different restorative materials, and to determine the accuracy of CBCT scans and periapical radiographs for the purpose of identifying peripheral gaps.

Material and methods

Study design and ethics committee

This was an *ex vivo* analytical experimental study that was approved by the Research Ethics Committee of the Federal University of Juiz de Fora (CEP/ UFJF, Juiz de Fora, Minas Gerais, Brazil), under opinion report No. 2,435,835 / 2017.

Sample preparation

For development of the research, an edentulous mandible with alveoli, made of barium, was used (Nacional Ossos, Jaú, SP, Brazil). This material simulates the characteristics of human radiographic bone density. For insertion into the mandible, 32 healthy mandibular teeth (31 molars and one premolar) were obtained from the Tooth Biobank of the UFJF School of Dentistry. One molar and premolar were used only for the purpose of allowing proximal contact with the sample teeth.

The thirty molars selected for the study had similar buccolingual and mesio-distal dimensions or presented a maximum variation of 10%. They were submitted to standardized preparations for a full crown with the aid of a condensation silicone model (Coltene, Altstätten, Switzerland). The walls were expulsive (approximately 6°) to facilitate accommodation of the prosthetic part. Occlusal and axial wear of 2 mm and 1.5 mm, respectively, was performed with a diamond-mounted tip, round-tipped conical trunk and medium granulation (# 4138). Finishing was performed with carbide drill (No.283). Conclusion of chamfer preparation and all internal angles were rounded [18]. The teeth were prepared by a single dentist, specialist in dentistry, and sent to a prosthetic laboratory for fabrication of the restorations.

The 30 teeth were randomly divided into two groups: All-ceramic Group: 15 teeth restored with full crowns had zirconia copings that were fabricated with Ceramill ZI White 71L (Amman Girrbach, Koblach, Austria), covered with feldspar ceramic (Kuraray Noritake Dental, Tokyo, Japan), so that we would have 10 teeth with marginal mismatches (0.3 and 0.5 mm) and five teeth with adequate marginal adaptation; Metal-ceramic Group: 15 teeth restored with full crowns made of Dan

Ceramalloy nickel-chrome alloy (Nihon Shika Kinzoku, Osaka, Japan), covered with the same feldspar ceramic used in the All-ceramic Group. Similarly, 10 teeth had gap (0.3 and 0.5 mm) and five teeth had well-adapted crowns.

In CAD-CAM (Ceramil Motion, Amann Girrbach, Koblach, Austria), zirconia copings and Ceramill Wax Gray 71L wax copings (Amann Girrbach, Koblach, Austria) were milled and then cast in metal. The inner surface of none of the copings was adjusted or worn. Gaps were made on the mesial or distal surfaces, randomly programmed by the CAD-CAM prosthetic device. No gaps were simulated on the buccal and lingual surfaces, since maladaptations on these surfaces can more easily be diagnosed during the clinical examination. Some authors consider marginal discrepancies between 50 and 150 μm to be clinically acceptable [19,20]. In the present study, marginal gaps were simulated in two sizes: 300 μm (0.3 mm) and 500 μm (0.5 mm), as the intention was to identify gaps that were detrimental to the integrity of the restoration, liable to allow infiltration. In a second stage, the copings were carefully covered with feldspar ceramic, so as not to conceal the marginal mismatch that was simulated in the previous stage.

The crowns were not cemented, only accommodated, so that the cement would not conceal possible mismatches and simulated gaps. To accommodate the crown, a 50 N snap force was standardized on the occlusal surface of the crown, perpendicular to the long axis of the tooth [4].

The restored teeth were inserted into the alveoli and fixated with the aid of utility wax (Technew, Rio de Janeiro, Brazil). Each restored tooth was positioned between two healthy teeth, one premolar in the mesial position and one molar located distally to simulate the point of contact. The healthy teeth were always the same and placed in the same position, and only the restored tooth was changed. For each restored tooth, digital periapical radiography and CBCT scans were performed with variation in the voxel size.

Radiographic density of the gum and facial soft tissue was simulated with the aid of utility wax, positioned on the buccal and lingual surface of the 15 mm thick mandible [21,22].

Image examinations

The mandible with properly positioned teeth was submitted to CBCT exams at the FO/ UFJF Dental Radiology Clinic (Juiz de Fora, Minas Gerais, Brazil) using the I-Cat® Next Generation appliance (Imaging Sciences International, Hatfield, Pennsylvania, USA), with the following acquisition protocol: 120 kV, 8 mA and 360 ° rotation, 5 x 13 cm FOV (field of view). Two voxel sizes were used: 0.25 mm and 0.30 mm.

Periapical radiographs of the teeth were also taken using the parallelism technique. The teeth were positioned in the mandible with the long axis perpendicular to the occlusal plane, with the film accommodated on the lingual surface and parallel to the teeth so that the x-ray beam was perpendicular to the proximal surfaces. Images were taken with the Heliodent Plus® periapical radiograph (Sirona, Bensheim, Germany) and the VistaScan direct digital system (Durr Dental, Bietigheim-Bissingen, Germany) with the following protocol: exposure time 0.32 s, 7 mA DC and 60-70 kVp.

For each restored tooth, a radiographic acquisition and two tomographic acquisitions with different resolutions were performed, one with a voxel size of 0.25 mm and the other with 0.30 mm.

Objective Analysis - Quantification of artifacts

After the acquisition of the tomographic images, they were stored decompressed in DICOM format (Digital Imaging and Communications in Medicine). The most cervical axial sections containing the entire restoration were selected. These sections were individually defined for each tooth and evaluated using ImageJ software (U.S. National Institutes of Health, Bethesda, Maryland, USA). Four rectangular regions of interest (ROIs) of standardized dimensions (8 x 3 mm) were selected. These ROIs included the mesial, distal, buccal and lingual regions of the tooth to be analyzed (Fig. 1).

Fig. 1

For each selected ROI, the artifacts were quantified based on the methodology of Pauwels et al. [23]. Still on ImageJ software, using the “Analyze – Histogram” tools, the minimum and maximum grayscale values were determined to calculate the actual standard deviation (SD). Using a 16-bit scale (65,536 gray values), since the images generated from the tomograph used in this study had this characteristic, the theoretical maximum standard deviation (SD) was determined, the value of which was half of the gray value of a 16-bit image, i.e. 32,768. The actual SD was converted into a percentage of the theoretical maximum SD, where higher percentages indicate more pronounced artefacts. The calculation was performed as follows: $\text{actual SD/theoretical maximum SD} \times 100$.

The artifact for each restored tooth was defined as an average of the four ROI measurements. The selection of axial sections and quantification of artifacts was performed by a single experienced CBCT examiner. To measure the reproducibility of the method, 30% of the exams were evaluated at two different times, with a two-week interval between them, in order to calculate intraobserver agreement.

Subjective Analysis - Crown gap assessment

Five blinded radiologists (unaware of the distribution of teeth in the two groups) evaluated tomographic and radiographic images. Evaluations were made on the same computer ASUSTek (Taipei, Taiwan), Intel® Core™ i5-4440 processor with a Samsung monitor (Seoul, South Korea) 18.5 inches, screen resolution 1366 x 768, 32-bit color depth, and Windows 7 Ultimate software in an environment with dim light. Radiographic images were randomly arranged on Power Point (Microsoft Store, USA) and saved in PDF for evaluation. The tomographic images could be freely evaluated by the examiners.

Examiners independently assessed the proximal (mesial and distal) surfaces of each tooth for gaps in the restored teeth. A scale of five scores was used: 1- definitely absent gap; 2- probably absent gap; 3- uncertainty about absence or presence of gap; 4- probably present gap; 5- definitely present gap.

In order to measure the reproducibility of the method, all examinations were evaluated at two different times, with a two-week interval between them, to calculate intra and interobserver agreement.

Data analysis

Data analysis was performed using SPSS (Statistical Package for Social Sciences, version 22.0, Chicago, USA), with a significance level of 5% ($p \leq 0.05$).

Objective Analysis

In order to verify intra-examiner agreement on artifact values, the intraclass correlation coefficient (ICC) was applied. Since the data did not present normal distribution by the Shapiro-Wilk test ($p < 0.05$), the nonparametric Mann-Whitney test was applied to compare the crowns (metal-ceramic and all-ceramic) and the CBCT exam resolutions (0.25 mm and 0.30 mm).

Subjective Analysis

In order to calculate intra and interobserver agreement, the Kappa coefficient was used. To verify the accuracy of the tests tested (CBCT voxel size of 0.25 mm, CBCT voxel size of 0.30 mm and periapical radiography) for the diagnosis of gaps in indirect restorations, the area under the ROC curve was determined for each evaluator. The comparison between the tested exams was made by using the Kruskal-Wallis and Student-Newman-Keuls tests.

Results

Objective Analysis

ICC of 30% of the sample indicated excellent intra-examiner agreement (ICC = 0.9923/ $p < 0.0001$).

The artifact values generated by the two types of crowns (metal-ceramic and all-ceramic) in the two CBCT image resolutions are shown in Table 1. The highest artifact values were observed to be associated with the ROIs located on the proximal surfaces (mesial and distal).

When the artifacts generated between the metal-ceramic and all-ceramic crowns were compared along with the different resolutions of CBCT images, no significant difference was observed in the values of these artifacts for any of the parameters tested (Table 2).

Table 1. Mean (standard deviation) quantification values of artifacts generated by the two types of crowns (metal-ceramic and all-ceramic) at the two CBCT image resolutions (0.25 mm and 0.30 mm)

	Voxel	Buccal	Lingual	Mesial	Distal	Total
Metal-ceramic	0.25 mm	2.78 (0.98)	3.97 (1.98)	8.19 (1.30)	9.30 (1.02)	6.07 (3.08)
All-ceramic		3.19 (1.67)	4.27 (1.72)	6.14 (2.23)	9.66 (1.10)	5.78 (3.01)
Metal-ceramic	0.30 mm	2.72 (1.25)	3.60 (1.82)	7.03 (1.03)	8.77 (1.11)	5.55 (2.81)
All-ceramic		3.16 (1.37)	3.57 (1.17)	5.93 (2.09)	8.55 (1.06)	5.29 (2.62)

Table 2. Comparison between metal-ceramic and all-ceramic crowns and among different CBCT image resolutions (voxel) on artifact production.

	Metal-ceramic	All-ceramic	p value*
Voxel	Mean (SD)	Mean (SD)	
0.25 mm	6.07 (3.08)	5.78 (3.01)	0.4066
0.30 mm	5.55 (2.81)	5.29 (2.62)	0.3567
p value*	0.1034	0.1555	

* Teste de Mann-Whitney

Subjective Analysis

Kappa coefficients indicated moderate to almost perfect intra-examiner agreement, and the highest values were observed for periapical radiographs. Values ranged from 0.4558 (moderate agreement) to 0.8935 (near perfect agreement) for tomographic images and from 0.7208 (substantial agreement) to 0.9823 (near perfect agreement) for radiographic images. For interexaminer agreement, the kappa coefficients indicated a fair to almost perfect agreement, and again the highest

values were observed for radiographs. When it came to the CBCT values, the variation ranged from 0.2183 (fair agreement) to 0.5967 (moderate agreement). For periapical radiographs, the values ranged from 0.6325 (substantial agreement) to 0.8414 (almost perfect agreement) [24].

Figures 2, 3 and 4 show the ROC curves obtained from the responses of each evaluator regarding the gap diagnosis for the three types of images tested. In Table 3 the values of the areas under the ROC curves were shown. Only for the smallest gaps (0.30 mm), the periapical radiographs were observed to be more accurate than the CBCT scans with voxel size of 0.30 mm. For larger gaps (0.50 mm) or when considered together (irrespective of size), no statistically significant difference was observed between the different types of images tested.

Figure 5 illustrates images of periapical radiographs and CBCTs for the two marginal gap sizes used.

Fig. 2, 3 and 4

Table 3. Accuracy, defined by the area under the ROC curve, for the diagnosis of gaps obtained in different imaging exams.

		ROC Area		
		Gap 0.30 mm	Gap 0.50 mm	Gap 0.30 e 0.50 mm
Examiner 1	CBCT 0.25 mm	0.790	0.535	0.668
	CBCT 0.30 mm	0.578	0.623	0.599
	Radiography	0.967	0.707	0.819
Examiner 2	CBCT 0.25 mm	0.867	0.635	0.847
	CBCT 0.30 mm	0.730	0.687	0.668
	Radiography	0.925	0.715	0.883
Examiner 3	CBCT 0.25 mm	0.647	0.713	0.678
	CBCT 0.30 mm	0.643	0.543	0.572
	Radiography	0.983	0.685	0.818
Examiner 4	CBCT 0.25 mm	0.960	0.590	0.772
	CBCT 0.30 mm	0.797	0.632	0.694
	Radiography	0.910	0.732	0.795
Examiner 5	CBCT 0.25 mm	0.970	0.852	0.913
	CBCT 0.30 mm	0.782	0.865	0.832
	Radiography	0.983	0.687	0.834
Mean	CBCT 0.25 mm	0.846 ab	0.665 a	0.775 a
	CBCT 0.30 mm	0.706 b	0.670 a	0.673 a
	Radiography	0.953 a	0.705 a	0.829 a
P value		0.014*	0.436	0.103

* Means followed by different letters show statistically significant differences by Kruskal-Wallis and Student-Newman-Keuls tests.

Fig. 5

Discussion

CBCT has a large number of indications in dentistry, including implant planning, diagnosis and surgical planning of included teeth and maxillofacial pathologies, detection of congenital dental and bone anomalies, in cases of dental and maxillofacial trauma, temporomandibular joint disorders (TMJ), orthodontic planning, and long-term treatment follow-up [9,11,15]. Moreover, even when it is not the primary indication for obtaining the exam, CBCT can be a useful tool to check for other changes [15], including the presence of cavities and marginal gaps, since this mismatch may result in damage to the tooth, periodontal tissues and restoration [25,26].

Some studies have shown that cavities detection rates in CBCT scans are approximately equivalent to those of intraoral radiographs for unrestored teeth [16,27]. However, the quality of the images obtained may be impaired by the presence of metal-generated artifacts [14,16], usually present in dental restorations, crowns, implants, as well as orthodontic appliances and prostheses, which may compromise the diagnosis [2].

An artifact is defined as any image distortion that is not present in the object under study [28-30]. When high-density objects are irradiated, they have an effect called beam hardening. The resulting image is altered, with the formation of hypodense bands, hyperdense streaks and distortion of objects, thus forming the artifact [10,11,31,32]. Artifacts caused by beam hardening occur due to differences in attenuation and absorption of X-ray beams upon contact with high density material and are influenced by object characteristics, such as density and atomic number [30,33-35].

In this study, we used metal-ceramic crowns and zirconia crowns. Metal-ceramic crowns have been used in dentistry for over 40 years and were considered the gold standard for many years [36,37]. This can be explained by their high degree of strength, obtained through the base, and good biocompatibility [38-40]. Ceramic restorations containing zirconia are very promising, not only due to their satisfactory aesthetic potential when compared with metals [41], but also due to the high flexural strength and fracture toughness [42], allowing less invasive dental preparations to be made [43].

Commonly, zirconia-based restorations and steel-framed restorations are covered with a ceramic coating, such as feldspar ceramic, which is widely used to improve aesthetic quality, as zirconia has the disadvantage of being an essentially white and opaque material, and metal restorations detract from aesthetics by darkening the remaining and marginal tissues [37,44].

Despite the atomic number of zirconium ($Z = 40$) being relatively high when compared with other metals such as nickel ($Z = 28$) and chromium ($Z = 24$), in the present study there was no significant difference in the number of artifacts generated in the images of the metal-ceramic crowns when compared with images of the all-ceramic crowns. Vasconcelos et al. [29] also found that zirconium implants behaved similarly to other metal dental restorative materials in terms of the production of CBCT image artifacts. CBCT images obtained with different resolutions (voxel sizes) also had no influence the quantity of artifacts generated by the different materials, corroborating the findings of studies by Pauwels et al. [23] and Vasconcelos et al. [29].

Regarding the higher values of artifacts found in ROIs located on the proximal (mesial and distal) surfaces, greater interference of these artifacts on adjacent teeth could be suggested, making it even more difficult to visualize pathologies or alterations in these regions. According to Freitas, Vasconcelos and Noujeim [12], in the case of crown evaluation, artifacts may imitate a fracture line or a mismatch, which may result in a false positive result or compromise the diagnosis of pathologies.

A major differential of this study was to evaluate the artifacts not only quantitatively, but also their influence on clinical images, assessing the real interference of these unwanted effects on the diagnosis of prosthetic mismatches. According to Mc Guigan et al. [45], both quantitative and quality evaluation of clinical images is necessary to ensure that an adequate diagnostic value is obtained.

Considering the examiners' responses relative to the presence or absence of crown gaps, it can be observed that for the larger gaps (0.50 mm) or when considered together (irrespective of the gap size), no significant difference was observed in the accuracy of gaps between the different types of images tested. These results correlated with those of objective analysis, since there was no difference in the quantification of artifacts between tomographic images of different

resolutions. However, for smaller gaps (0.30 mm), the radiographs were significantly more accurate than the CBCT scans with voxel size of 0.30 mm, which may be justified by the fact that larger voxel sizes resulted in lower image resolution, which could affect the diagnostic quality of fine details [29]. When the accuracy of the two tomographic exams was compared, no difference between them could be observed, once again correlating with the results of artifact quantification that indicated no difference between these exams.

Worth highlighting is that this study did not evaluate other factors that influence image formation, such as kV, mA, FOV (field of view) and position of the image object within the FOV, which may also have an effect on the amount of artifacts generated and the diagnosis of marginal gaps [45-49].

Conclusions

It could be concluded that in spite of being two-dimensional, periapical radiography is still the best cost-benefit tool for the diagnosis of maladaptation in dental restorations at the tooth–material interface, with advantages in both the accuracy of the diagnosis, costs and radiation dose. However, although CBCT with a voxel size of 0.25 mm is not the first choice for gap diagnosis, if the patient already has these images that were obtained for other indications, they could be used to evaluate possible marginal mismatches.

Compliance with Ethical Standards

Conflict of Interest: Author Letícia Queiroz Mauad declares that he has no conflict of interest. Author Karolina Aparecida Castilho Fardim declares that he has no conflict of interest. Author Alessiana Helena Machado declares that he has no conflict of interest. Author Paulo Victor Teixeira Doriguêto declares that he has no conflict of interest. Author Daniela de Almeida declares that he has no conflict of interest. Author Karina Lopes Devito declares that he has no conflict of interest.

Funding: This study was financed by the Coordenação de Aperfeiçoamento de Pessoal de Nível Superior - Brazil (CAPES) - Finance Code 001.

Ethical approval: This article was approved by the Research Ethics Committee of the Federal University of Juiz de Fora (CEP/ UFJF, Juiz de Fora, Minas Gerais, Brazil), under opinion report No. 2,435,835 / 2017.

Informed consent: For this type of study, formal consent is not required.

References

1. Chabouis HF, Faugeron VS, Attal JP (2013) Clinical efficacy of composite versus ceramic inlays and onlays: a systematic review. *Dent Mater* 29:1209-1218.
2. Rozylo-Kalinowska I, Miechowicz S, Sarna-Bos K, Borowicz J, Kalinowski P (2014) Analysis of vector models in quantification of artifacts produced by standard prosthetic inlays in cone-beam computed tomography (CBCT) – a preliminary study. *Postepy Hig Med Dosw* 68:1343-1346.
3. Borba M, Miranda Jr WG, Cesar PF, Griggs JA, Bona AD (2013) Evaluation of the adaptation of zirconia-based fixed partial dentures using micro-CT technology. *Braz Oral Res* 27:396-402.
4. Riccitiello F, Amato M, Leoa R, Spagnuolo G, Sorrentino R (2018) In vitro evaluation of the marginal fit and internal adaptation of zirconia and lithium disilicate single crowns: micro-CT comparison between different manufacturing procedures. *Open Dent J* 22:160-172
5. Kamburoglu K, Kolsuz E, Murat S, Yuksel S, Ozen T (2012) Proximal caries detection accuracy using intraoral bitewing radiography, extraoral bitewing radiography and panoramic radiography. *Dentomaxillofac Radiol* 41:450-459.
6. Murat S, Kamburoglu K, Isayev A, Kursun S, Yuksel S (2013) Visibility of artificial buccal recurrent caries under restorations using different radiographic techniques. *Oper Dent* 38:197-207.
7. Wenzel A, Hirsch E, Christensen J, Matzen LH, Scaf G, Frydenberg M (2013) Detection of cavitated approximal surfaces using cone beam CT and intraoral receptors. *Dentomaxillofac Radiol* 42:39458105.
8. Abu El-Ela WH, Farid MM, Mostafa MSE (2016) Intraoral versus extraoral bitewing radiography in detection of enamel proximal caries: an ex vivo study. *Dentomaxillofac Radiol* 45:20150326.
9. Vedpathak PR, Gondivkar SM, Bhoosreddy AR, Shah KR, Verma G, Mehrotra GP, Nerkar AC (2016) Cone beam computed tomography - an effective tool in detecting caries under fixed dental prostheses. *J Clin Diagn Res* 10:ZC10-13.
10. Kuusisto N, Vallittu PK, Lassila LVJ, Huuonen S (2015) Evaluation of intensity of artefacts in CBCT by radio-opacity of composite simulation models of implants in vitro. *Dentomaxillofac Radiol* 44:20140157.

11. Omar G, Abdelsalam Z, Hamed W (2016) Quantitative analysis of metallic artifacts caused by dental metallic restorations: comparison between four CBCT scanners. *Future Dent J* 2:15-21.
12. Freitas DQ, Vasconcelos TV, Noujeim M (2019) Diagnosis of vertical root fracture in teeth close and distant to implant: an in vitro study to assess the influence of artifacts produced in cone beam computed tomography. *Clin Oral Invest* 23:1263-1270.
13. Park H, Min C, Kim K, Koh K (2019) Optimization of exposure parameters and relationship between subjective and technical image quality in cone-beam computed tomography. *Imaging Sci Dent* 49:139-151.
14. Gong XY, Meyer E, Yu XJ, Sun JH, Sheng LP, Huang KH, Wu RZ (2013) Clinical evaluation of the normalized metal artefact reduction algorithm caused by dental fillings in CT. *Dentomaxillofac Radiol* 42:20120105.
15. Kulczyk T, Dyszkiewicz Konwinska M, Owecka M, Krzyzostaniak J, Surdacka A (2014) The influence of amalgam fillings on the detection of approximal caries by cone beam CT: in vitro study. *Dentomaxillofac Radiol* 43:20130342.
16. Gaalaas I, Tyndall D, Mol A, Everett ET, Bangdiwala A (2016) Ex vivo evaluation of new 2D and 3D dental radiographic technology for detecting caries. *Dentomaxillofac Radiol* 45:20150281.
17. Kuusisto N, Huuonen S, Kotiaho A, Haapea M, Rekola J, Vallittu P (2019) Intensity of artefacts in cone beam CT examinations caused by titanium and glass fibre-reinforced composite implants. *Dentomaxillofac Radiol* 48:20170471.
18. Pedroche LO, Bernardes SR, Leão MP, Kintopp CCA, Correr GM, Ornaghi BP, Gonzaga CC (2016) Marginal and internal fit of zirconia copings obtained using different digital scanning methods. *Braz Oral Res* 30:e113-119.
19. Reich S, Kappe K, Teschner H, Schmitt J (2008) Clinical fit of four-unit zirconia posterior fixed dental prostheses. *Eur J Oral Sci* 116:579–584.
20. Habib SR, Ajmi MG, Dhafyan M, Jomah A, Abualsaud H, Almashali M (2017) Effect of margin designs on the marginal adaptation of zirconia copings. *Acta Stomatol Croat* 51:179-187.

21. Schropp L, Alyass NS, Wenzel A, Stavropoulos A (2012) Validity of wax and acrylic as soft-tissue simulation materials used in in vitro radiographic studies. *Dentomaxillofac Radiol* 41:686-690.
22. Neves FS, Freitas DQ, Campos PSF, Ekestubbe A, Lofthag-hansen S (2014) Evaluation of cone-beam computed tomography in the diagnosis of vertical root fractures: the influence of imaging modes and root canal materials. *J Endod* 40:1530-1536.
23. Pauwels R, Stamatakis H, Bosmans H, Bogaerts R, Jacobs R, Horner K, Tsiklakis K, SEDENTEXCT Project Consortium (2013) Quantification of metal artifacts on cone beam computed tomography images. *Clin Oral Impl Res* 24:94-99.
24. Landis JR, Koch G (1977) An application of hierarchical kappa-type statistics in the assessment of majority agreement among multiple observers. *Biometrics* 33:363-437.
25. Abduo J, Lyons K, Swain M (2010) Fit of zirconia fixed partial denture: a systematic review. *J Oral Rehabil* 37:866-876.
26. Borba M, Cesar PF, Griggs JA, Della Bona A (2011) Adaptation of all-ceramic fixed partial dentures. *Dent Mater* 27:1119-1126.
27. Senel B, Kamburoglu K, Uçok O, Yuksel SP, Zen TO, Avsever H (2010) Diagnostic accuracy of different imaging modalities in detection of proximal caries. *Dentomaxillofac Radiol* 39:501-511.
28. De Man B, Nuyts J, Dupont P, Marchal G, Suetens P (2000) Reduction of metal streak artifacts in x-ray computed tomography using a transmission maximum a posteriori algorithm. *IEEE Trans Nucl Sci* 47:977-981.
29. Vasconcelos TV, Bechara BB, McMahan CA, Freitas DQ, Noujeim M (2017) Evaluation of artifacts generated by zirconium implants in cone-beam computed tomography images. *Oral Surg Oral Med Oral Pathol Oral Radiol* 123:265-272.
30. Demirturk Kocasarac H, Ustaoglu G, Bayrak S, Katkar R, Geha H, Deahl ST 2nd, Mealey BL, Danaci M, Noujeim M (2019) Evaluation of artifacts generated by titanium, zirconium, and titanium-zirconium alloy dental implants on MRI, CT, and CBCT images: A phantom study. *Oral Surg Oral Med Oral Pathol Oral Radiol* 127:535-544.

31. Bechara B, Alex McMahan C, Moore WS, Noujeim M, Teixeira FB, Geha H (2013) Cone beam CT scans with and without artefact reduction in root fracture detection of endodontically treated teeth. *Dentomaxillofac Radiol* 42:20120245.
32. Shokri A, Jamalpour MR, Khavid A, Mohseni Z, Sadeghi M (2019) Effect of exposure parameters of cone beam computed tomography on metal artifact reduction around the dental implants in various bone densities. *BMC Med Imaging* 19:29-34.
33. Nummikoski PV, Martinez TS, Matteson SR, McDavid WD, Dove SB (1992) Digital subtraction radiography in artificial recurrent caries detection. *Dentomaxillofac Radiol* 21:59-64.
34. Schulze RK, Berndt D, d'Hoedt B (2010) On cone-beam computed tomography artifacts induced by titanium implants. *Clin Oral Implants Res* 21:100-107.
35. Oliveira ML, Tosoni GM, Lindsey DH, Mendoza K, Tetradis S, Mallya SM (2013) Influence of anatomical location on CT numbers in cone beam computed tomography. *Oral Surg Oral Med Oral Pathol Oral Radiol* 115:558-564.
36. Colpani JT, Borba M, Della Bona A (2013) Evaluation of marginal and internal fit of ceramic crown copings. *Dent Mater* 29:174-180.
37. Walton TR (2013) The up to 25-year survival and clinical performance of 2,340 high gold-based metal-ceramic single crowns. *Int J Prosthodont* 26:151–160.
38. Gardner FM, Tillman-McCombs KW, Gaston ML, Runyan DA (1997) In vitro failure load of metal-collar margins compared with porcelain facial margins of metal-ceramic crowns. *J Prosthet Dent* 78:1-4.
39. Ulusoy M, Toksavul S (2002) Fracture resistance of five different metal framework designs for metal-ceramic restoration. *Int J Prosthodont* 15:571–574.
40. Anmol C, Soni S (2014) Effect of two different finishing systems on surface roughness of feldspathic and fluorapatite porcelains in ceramo-metal restorations: Comparative in vitro study. *J Int Soc Prev Community Dent* 4:22-28.

41. Thompson JY, Stoner BR, Piascik JR, Smith R (2011) Adhesion/cementation to zirconia and other non-silicate ceramics: Where are we now? *Dent Mater* 27:71-82.
42. Sailer I, Balmer M, Hüsler J, Hammerle CHF, Kanel S, Thoma DS (2018) 10-year randomized trial (RCT) of zirconia-ceramic and metal-ceramic fixed dental prostheses. *J Dent* 76:32-39.
43. Kelly JR, Denry I (2008) Stabilized zirconia as a structural ceramic: An overview. *Dent Mater* 24:289-298.
44. Lee H, Kwon T (2017) The application of a novel ceramic liner improves bonding between zirconia and veneering porcelain. *Materials* 10:E1009-1023.
45. Mc Guigan MB, Duncan HF, Horner K (2018) An analysis of effective dose optimization and its impact on image quality and diagnostic efficacy relating to dental cone beam computed tomography (CBCT). *Swiss Dent J* 128:297-316.
46. Codari M, Vasconcelos KF, Nicolielo LFP, Haiter Neto F, Jacobs R (2017) Quantitative evaluation of metal artifacts using different CBCT devices, 23 high-density materials and field of views. *Clin Oral Implants Res* 28:1509-1514.
47. Alawaji Y, MacDonald DS, Giannelis G, Ford NL (2018) Optimization of cone beam computed tomography image quality in implant dentistry. *Clin Exp Dent Res* 4:268-278.
48. Machado AH, Fardim KAC, Souza CF, Sotto-Maior BS, Assis NMSP, Devito KL (2018) Effect of anatomical region on the formation of metal artefacts produced by dental implants in cone beam computed tomographic images. *Dentomaxillofac Radiol* 47:20170281.
49. Costa ED, Queiroz PM, Santaella GM, Capelozza ALA, Ambrosano GMB, Freitas DQ (2019) Influence of scan mode (partial/full rotations) and FOV size in the formation of artefacts in cone beam CT. *Dentomaxillofac Radiol* 48:20180340.

Figure legends

Fig. 1 CBCT axial section illustrating the four ROIs positioned for quantifying artifacts

Fig. 2 ROCs curves showing comparison of accuracy of the three types of images for the diagnosis of 0.30 mm gap, evaluated by the five evaluators (a-e)

Fig. 3 ROCs curves showing comparison of accuracy of the three types of images for the diagnosis of 0.50 mm gap, evaluated by the five evaluators (a-e)

Fig. 4 ROC curves showing comparison of the accuracy of the three types of images for the diagnosis of gaps (0.30 mm and 0.50 mm), evaluated by the five evaluators (a-e)

Fig. 5 Images of periapical and CBCT illustrating different gap sizes in metal-ceramic and all-ceramic crowns

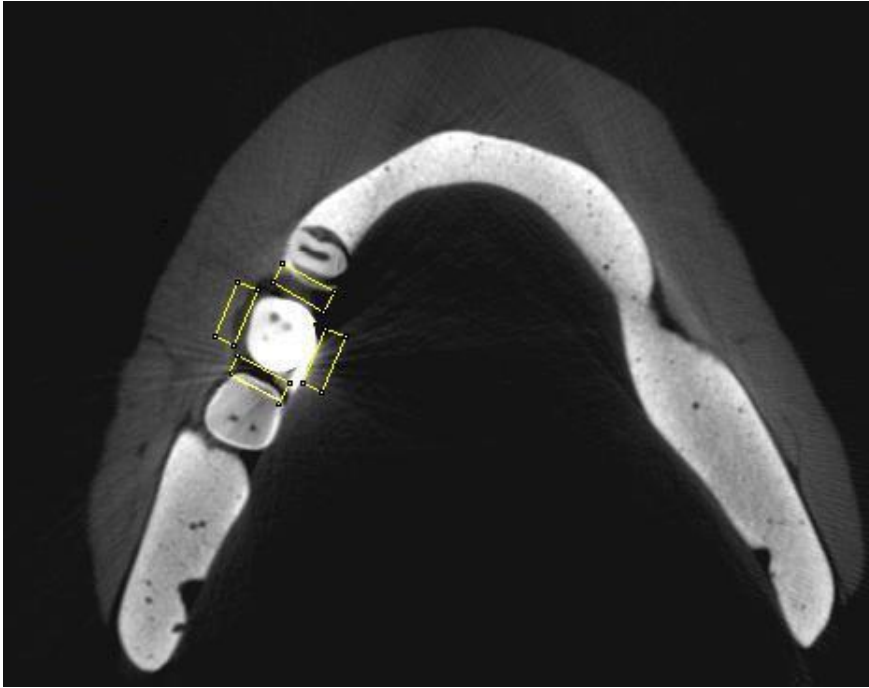


Fig.1

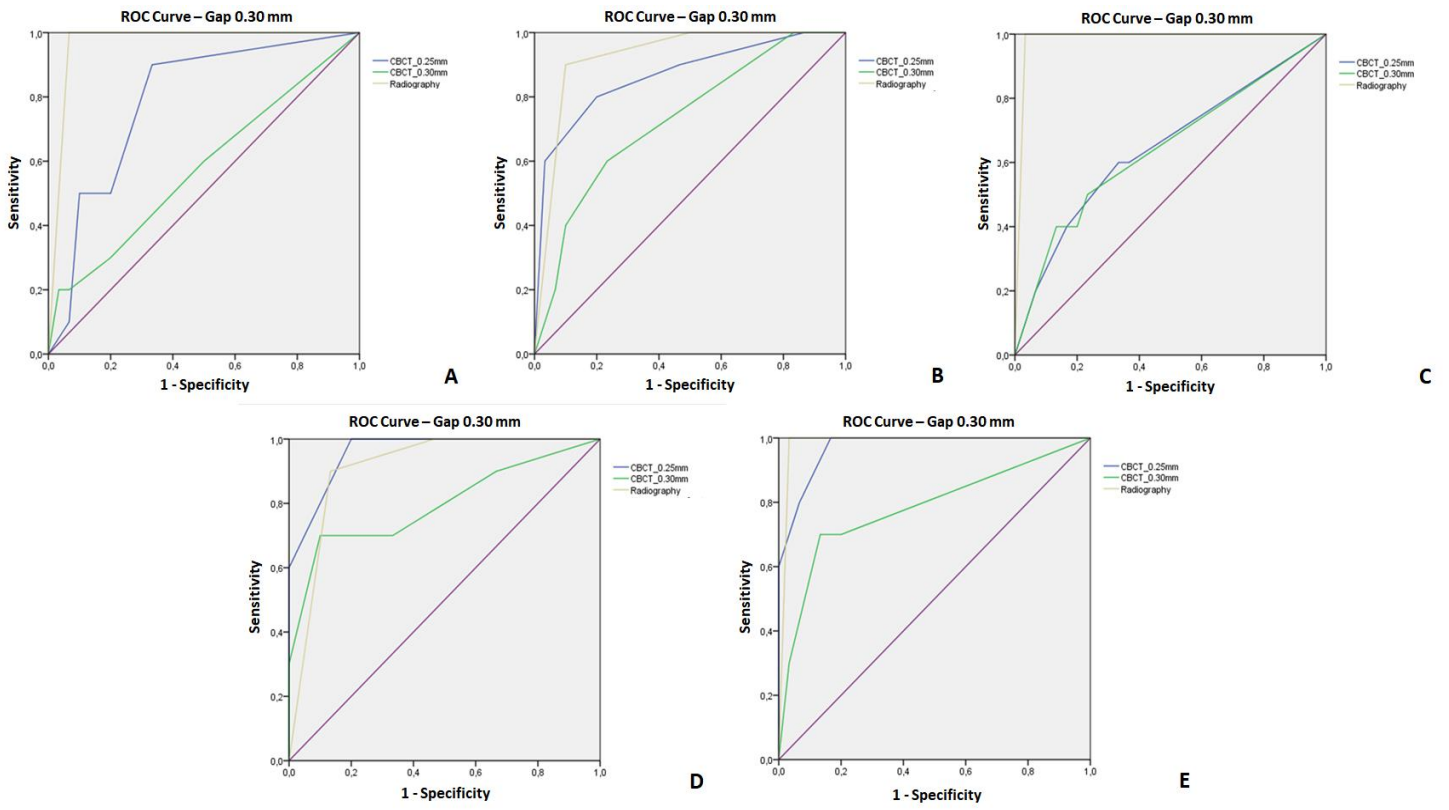


Fig.2

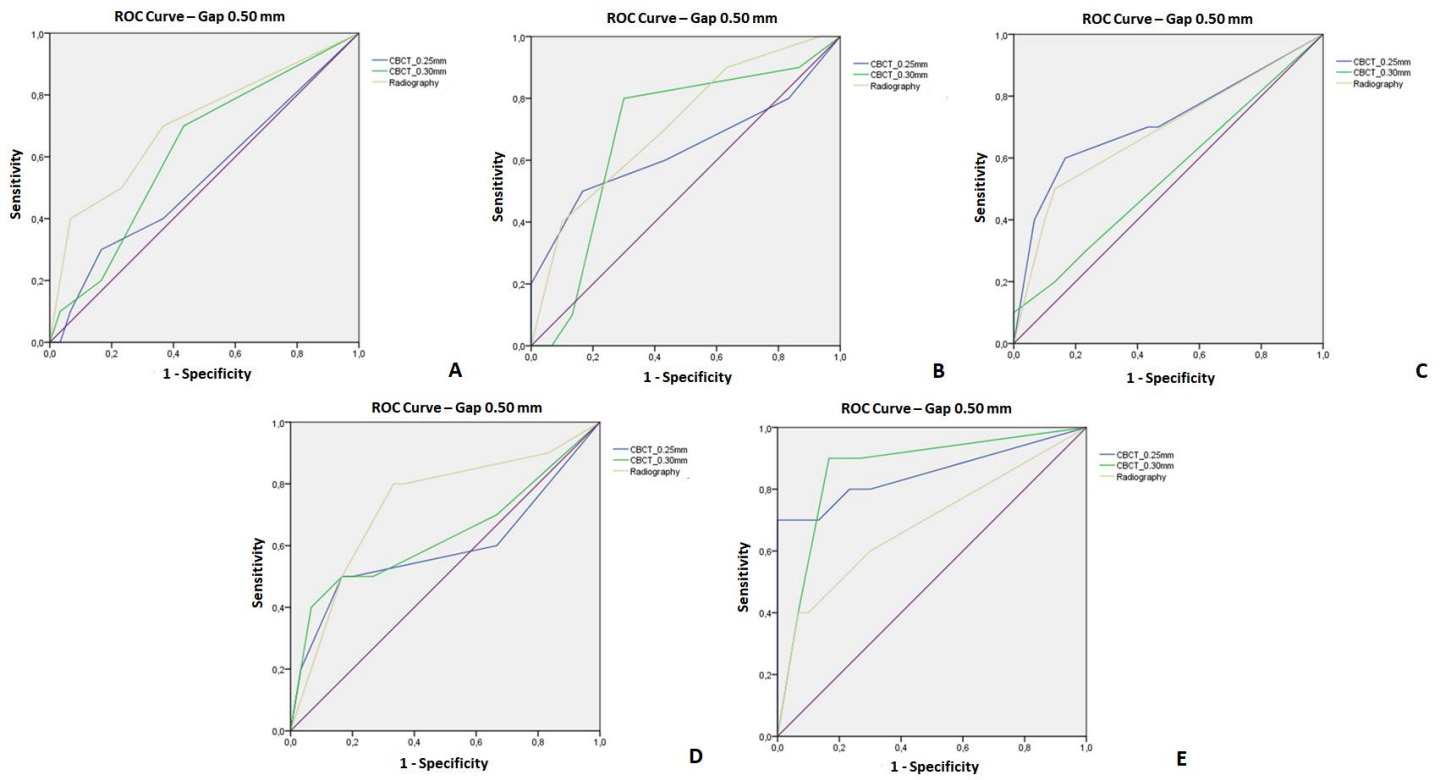


Fig.3

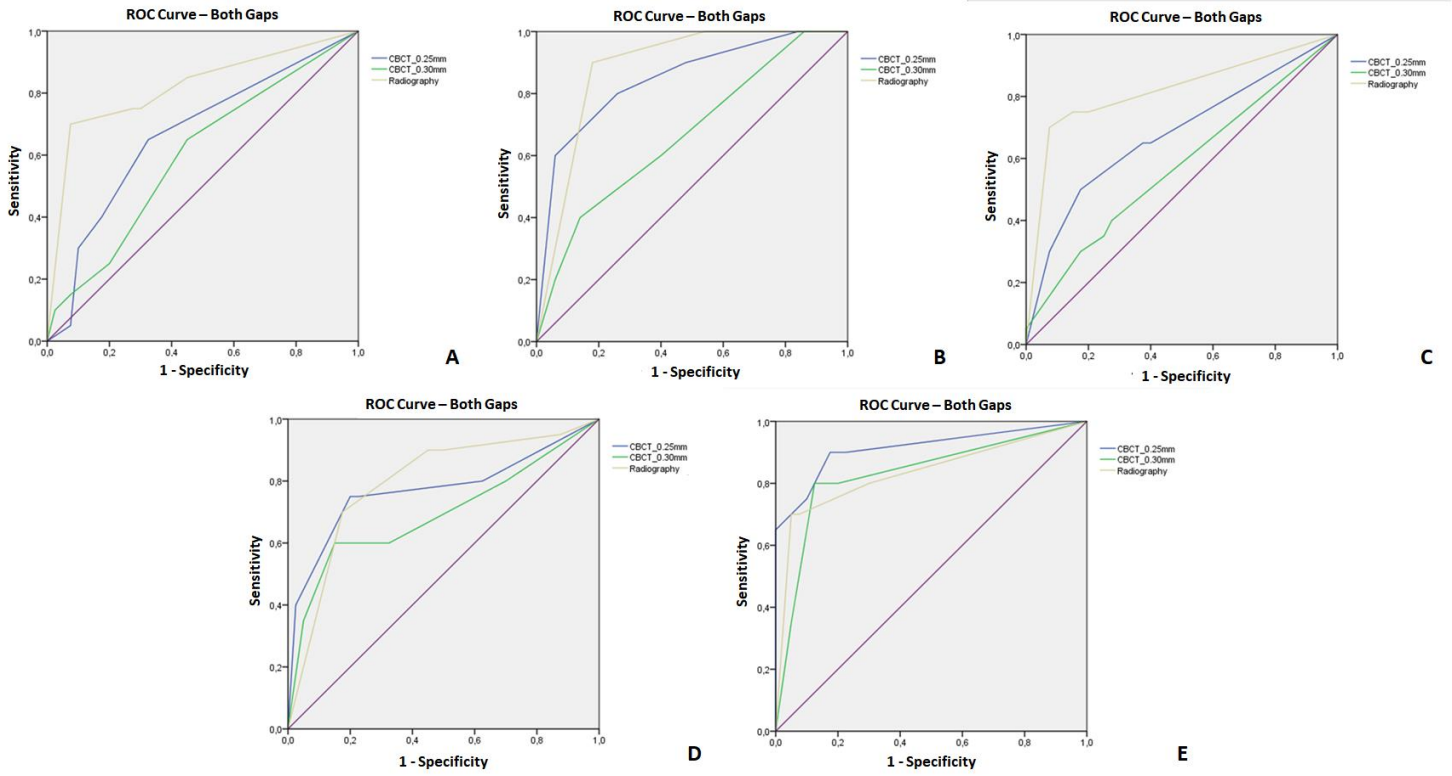


Fig.4

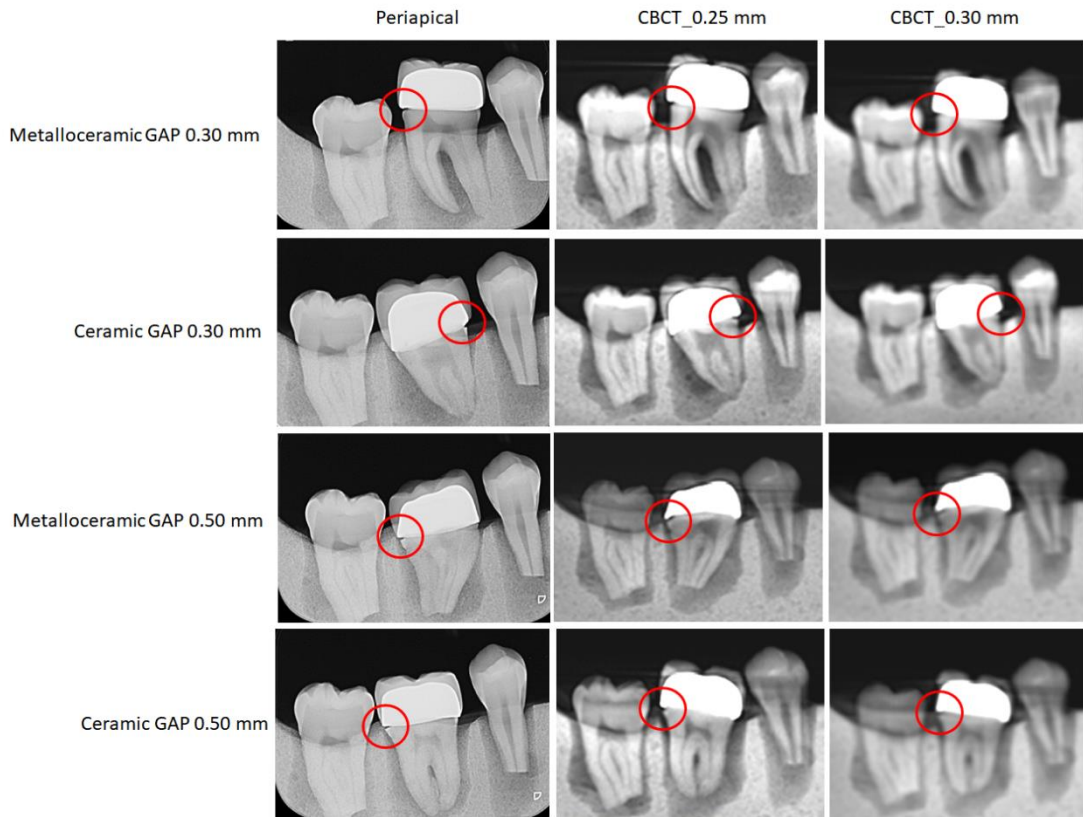


Fig.5

5 CONSIDERAÇÕES FINAIS

Pode-se concluir que a quantidade de artefatos gerados pelas coroas metalocerâmica e cerâmica pura em imagens de TCFC é semelhante. Os maiores valores de artefatos foram associados às faces proximais dos dentes.

Em relação à acurácia dos exames testados para o diagnóstico de *gaps* proximais em restaurações dentárias, a radiografia periapical e a TCFC com voxel de 0,25 mm, apresentaram o melhor desempenho para os *gaps* de menores dimensões (0,30 mm). Para *gaps* maiores (0,50 mm), todos os exames testados mostraram o mesmo desempenho.

REFERÊNCIAS

- ABDUO J, LYONS K, SWAIN M. Fit of zirconia fixed partial denture: a systematic review. **J Oral Rehabil**, v. 37, n.11, p. 866-876, Nov. 2010.
- ABU EL-ELA, W. H.; FARID, M. M.; MOSTAFA, M. S. E. Intraoral versus extraoral bitewing radiography in detection of enamel proximal caries: an ex vivo study. **Dentomaxillofac Radiol**, v.45, n. 4, 2016.
- ALAWAJI, Y.; MACDONALD, D. S.; GIANNELIS, G.; FORD, N. L. Optimization of cone beam computed tomography image quality in implant dentistry. **Clin Exp Dent Res**, v. 4, p. 268-278, 2018.
- ANMOL, C., SONI, S. Effect of two different finishing systems on surface roughness of feldspathic and fluorapatite porcelains in ceramo-metal restorations: Comparative *in vitro* study. **J Int Soc Prev Community Dent**, v.4, n.1, p. 22-28, 2014.
- BECHARA, B.; ALEX MCMAHAN, C.; MOORE, W.S.; NOUJEIM, M.; TEIXEIRA, F.B.; GEHA, H. Cone beam CT scans with and without artefact reduction in root fracture detection of endodontically treated teeth. **Dentomaxillofac Radiol**, v. 42, n. 5, p. 2012-2045, 2013.
- BORBA, M., CESAR, P. F., GRIGGS, J. A., DELLA BONA, A. Adaptation of all-ceramic fixed partial dentures. **Dent Mater**, v.27, n.11, p.1119-1126, 2011.
- BORBA, M., MIRANDA JR, W. G., CESAR, P. F., GRIGGS, J. A., DELLA BONA, A. Evaluation of the adaptation of zirconia-based fixed partial dentures using micro-CT technology. **Braz Oral Res**, v.27, n.5, p.396-402, 2013.
- CHABOUIS H. F.; FAUGERON V. S.; ATTAL J.P. Clinical efficacy of composite versus ceramic inlays and onlays: a systematic review. **Dent Mater**, v.29, n.12, p.1209-1218, 2013.
- CODARI, M.; VASCONCELOS, K. F.; NICOLIELO L. F. P.; HAITER NETO, F.; JACOBS, R. Quantitative evaluation of metal artifacts using different CBCT devices, 23 high-density materials and field of views. **Clin Oral Implants Res**, v. 28, n.12, p. 1509-1514, 2017.
- COLPANI, J. T.; BORBA, M.; DELLA BONA, A. Evaluation of marginal and internal fit of ceramic crown copings. **Dent Mater**, v. 29, n. 2, p. 174-180, 2013.

COSTA, E. D.; QUEIROZ, P. M.; SANTAELLA, G. M.; CAPELOZZA, A. L. A.; AMBROSANO, G. M. B.; FREITAS, D. Q. Influence of scan mode (partial/fullrotations) and FOV size in the formation of artefacts in cone beam CT. **Dentomaxillofac Radiol**, v. 48, 2019.

DE MAN, B.; NUYTS, J.; DUPONT, P.; MARCHAL, G.; SUETENS, P. Reduction of metal streak artifacts in x-ray computed tomography using a transmission maximum a posteriori algorithm. **IEEE Trans Nucl Sci**, v. 47, n. 3, p. 977-981, 2000.

DEMIRTURK KOCASARAC, H.; USTAOGU, G.; BAYRAK, S.; KATKAR, R.; GEHA, H.; DEAHL, T.; MEALEY, B.; DANACI, M.; NOUJEIM, M. Evaluation of artifacts generated by titanium, zirconium, and titanium zirconium alloy dental implants on MRI, CT, and CBCT images: A phantom study. **Oral Surg Oral Med Oral Pathol Oral Radiol**, v. 127, n. 6, p. 535-544, 2019.

FREITAS, D. Q.; VASCONCELOS, T. V.; NOUJEIM, M. Diagnosis of vertical root fracture in teeth close and distant to implant: an in vitro study to assess the influence of artifacts produced in cone beam computed tomography. **Clin Oral Invest** v. 23, p. 1263–1270, 2019.

GAALAAS, I.; TYNDALL, D.; MOL, A.; EVERETT, E. T.; BANGDIWALA, A. Ex vivo evaluation of new 2D and 3D dental radiographic technology for detecting caries. **Dentomaxillofac Radiol**, v. 45, 2016.

GARDNER, F. M., TILLMAN-MCCOMBS, K. W., GASTON, M. L., RUNYAN, D. A., In vitro failure load of metal-collar margins compared with porcelain facial margins of metal-ceramic crowns, **J Prosthet Dent**, v.78, n.1, p.1–3, 1997.

GONG, X. Y.; MEYER, E.; YU, X. J.; SUN, J. H.; SHENG, L. P.; HUANG, K. H.; WU, R. Z. Clinical evaluation of the normalized metal artefact reduction algorithm caused by dental fillings in CT. **Dentomaxillofac Radiol**, v. 42, 2013.

HABIB, S. R.; AJMI, M. G.; DHAFYAN, M.; JOMAH, A.; ABUALSAUD, H.; ALMASHALI, M. Effect of Margin Designs on the Marginal Adaptation of Zirconia Copings. **Acta Stomatol Croat**, v. 51, n. 3, p. 179-187, 2017.

KAMBUROGLU, K.; KOLSUZ, E.; MURAT, S.; YUKSEL, S.; OZEN, T. Proximal caries detection accuracy using intraoral bitewing radiography, extraoral bitewing radiography and panoramic radiography. **Dentomaxillofac Radiol**, v.41, p.450-459, 2012.

KELLY J. R.; DENRY, I. Stabilized zirconia as a structural ceramic: An overview. **Dent Mater**, v.24, p.289-298, 2008.

KULCZYK, T.; DYSZKIEWICZ KONWIŃSKA, M.; OWECKA, M.; KRZYŻOSTANIAK, J.; SURDACKA, A. The influence of amalgam fillings on the detection of approximal caries by cone beam CT: in vitro study. **Dentomaxillofac Radiol**, v. 43, 2014.

KUUSISTO, N.; VALLITTU, P. K.; LASSILA, L. V. J.; HUUMONEN, S. Evaluation of intensity of artefacts in CBCT by radio-opacity of composite simulation models of implants in vitro. **Dentomaxillofac Radiol**, v. 44, n. 2, 2015.

KUUSISTO, N.; HUUMONEN, S.; KOTIAHO, A.; HAAPEA, M.; REKOLA, J.; VALLITTU, P. Intensity of artefacts in cone beam CT examinations caused by titanium and glass fibre-reinforced composite implants. **Dentomaxillofac Radiol**, v. 48, n. 2, 2019.

LANDIS J. R.; KOCH G. G. An application of hierarchical kappa-type statistics in the assessment of majority agreement among multiple observers. **Biometrics**, v. 33, p. 363-437, 1977.

LEE, H.; KWON, T. The Application of a Novel Ceramic Liner Improves Bonding between Zirconia and Veneering Porcelain. **Materials**, v.10, p. 1009-1023, 2017.

MACHADO, A. H.; FARDIM, K. A. C.; SOUZA, C. F.; SOTTO-MAIOR, B. S.; ASSIS, N. M. S. P.; DEVITO, K. L. Effect of anatomical region on the formation of metal artefacts produced by dental implants in cone beam computed tomographic images. **Dentomaxillofac Radiol**, v. 47, 2018.

MURAT, S.; KAMBUROGLU, K.; ISAYEV, A; KURSUN, S.; YUKSEL, S. Visibility of artificial buccal recurrent caries under restorations using different radiographic techniques. **Oper Dent**, v. 38, n.2, p.197-207, 2013.

NEVES, F. S.; FREITAS, D. Q.;CAMPOS, P. S. F.; EKESTUBBE, A.; LOFTHAG-HANSEN, S. Evaluation of Cone-beam Computed Tomography in the Diagnosis of Vertical Root Fractures: The Influence of Imaging Modes and Root Canal Materials. **J Endod**, v.40, n.10, p.1530-1536, 2014.

NUMMIKOSKI, P. V.; MARTINEZ, T. S.; MATTESON, S. R.; MCDAVID, W. D.; DOVE, S. B. Digital subtraction radiography in artificial recurrent caries detection. **Dentomaxillofac Radiol.**, v. 21, p. 59-64, 1992.

OLIVEIRA, M. L.; TOSONI, G. M.; LINDSEY, D. H.; MENDOZA, K.;TETRADIS, S.; MALLYA, S. M. Influence of anatomical location on CT numbers in cone beam computed tomography. **Oral Surg Oral Med Oral Pathol Oral Radiol**, v. 115, n. 4, p. 558-564, Apr. 2013.

OMAR, G.; ABDELSALAM, Z; HAMED, W. Quantitative analysis of metallic artifacts caused by dental metallic restorations: Comparison between four CBCT scanners. **FDJ**, v.2, p. 15-21, 2016.

PARK, H.; MIN, C.; KIM, K.; KOH, K. Optimization of exposure parameters and relationship between subjective and technical image quality in cone-beam computed tomography. **Imaging Sci Dent**, v. 49, n. 2, p.139-151, 2019.

PAUWELS, R.; STAMATAKIS, H.; BOSMANS, H.; BOGAERTS, R.; JACOBS, R.; HORMER, K.; TSIKLAKIS, K. Quantification of metal artifacts on cone beam computed tomography images. **Clin Oral Impl Res**, v. 24, p. 94-99, 2013.

PEDROCHE, L. O., BERNARDES, S. R., LEÃO, M. P., KINTOPP, C. C. A., CORRER, G. M., ORNAGHI, B. P., GONZAGA, C. C. Marginal and internal fit of zirconia copings obtained using different digital scanning methods. **Braz Oral Res**, v.30, n.1, p.113-119, 2016.

REICH, S.; KAPPE, K.; TESCHNER, H.; SCHMITT, J.; Clinical fit of four-unit zirconia posterior fixed dental prostheses. **Eur J Oral Sci**, v. 116, p. 579–584, 2008.

RICCITIELLO, F.; AMATO, M.; LEOA, R.; SPAGNUOLO, G.; SORRENTINO, R. *In vitro* Evaluation of the Marginal Fit and Internal Adaptation of Zirconia and Lithium Disilicate Single Crowns: Micro-CT Comparison Between Different Manufacturing Procedures. **Open Dent J**, v.22, n. 12, p. 160-172, 2018.

ROZYLO-KALINOWSKA, I; MIECHOWICZ, S; SARNA-BOS , K; BOROWICZ, J; KALINOWSKI, P. Analysis of Vector Models in Quantification of Artifacts Produced by Standard Prosthetic Inlays in Cone-Beam Computed Tomography (CBCT) – a Preliminary Study. **Postepy Hig Med Dosw**, v. 68, p. 1343-1346, 2014.

SAILER, I.; BALMER, M.; HÜSLER, J.;HAMMERLE, C. H. F.; KANEL, S.; THOMA, D. S. 10-year randomized trial (RCT) of zirconia-ceramic and metal-ceramic fixed dental prostheses. **J Dent**, v. 76, p. 32-39, 2018.

SCHAEFER, O.; DECKER, M.; WITTSTOCK, F.; KUEPPER, H.; GUENTSCH, A. Impact of digital impression techniques on the adaption of ceramic partial crowns in vitro. **J Dent**, v. 42, p. 677-683, 2014.

SENEL, B.; KAMBUROGLU, K.; UÇOK, O.; YUKSEL, S. P.; ZEN, T. O.; AVSEVER, H. Diagnostic accuracy of different imaging modalities in detection of proximal caries. **Dentomaxillofac Radiol**, v. 39, p. 501–511, 2010.

SHOKRI, A.; JAMALPOUR, M. R.; KHAVID, A.; MOHSENI, Z.; SADEGHI, M. Effect of exposure parameters of cone beam computed tomography on metal artifact reduction around the dental implants in various bone densities. **BMC Med Imaging**, v.19, n.1, p. 29-34, 2019.

SCHROPP, L.; ALYASS, N. S.; WENZEL, A.; STAVROPOULOS, A. Validity of wax and acrylic as soft-tissue simulation materials used in in vitro radiographic studies. **Dentomaxillofac Radiol**, v. 41, p. 686-690, 2012.

SCHULZE, R. K.; BERNDT, D.; D'HOEDT, B. On cone-beam computed tomography artifacts induced by titanium implants. **Clin Oral Implants Res**, v. 21, n.1, p.100-107, Jan. 2010.

SIMÕES, C.C; CAMPOS, P.S.F. Influência do tamanho do voxel na qualidade de imagem tomográfica: revisão de literatura. **RFO-Passo Fundo**, v.18, n.3, p.361-364, 2013.

THOMPSON, J. Y., STONER, B. R., PIASCIK, J.R., SMITH, R. Adhesion/cementation to zirconia and other non-silicate ceramics: Where are we now? **Dent Mater**, v.27, n.1, p.71-82, 2011.

ULUSOY, M., TOKSAVUL, S. Fracture resistance of five different metal framework designs for metal-ceramic restoration. **Int J Prosthodont**, v.15, n.6, p.571–574, 2002.

VASCONCELOS, T. V.; BECHARA, B. B.; MCMAHAN, C. A.; FREITAS, D. Q.; NOUJEIM, M. Evaluation of artifacts generated by zirconium implants in cone-beam computed tomography images. **Oral Surg Oral Med Oral Pathol Oral Radiol**. V. 123, n. 2, p. 265-272, 2017.

VEDPATHAK, P. R.; GONDIVKAR, S. M.; BHOOSREDDY, A. R.; SHAH, K. R.; VERMA, G.; MEHROTRA, G. P.; NERKAR, A. C. Cone Beam Computed Tomography- An Effective Tool in Detecting Caries Under Fixed Dental Prostheses. **J Clin Diagn Res**, v. 10, n.8, p. 10-13, 2016.

WALTON, T. R.; The up to 25-year survival and clinical performance of 2,340 high gold-based metal-ceramic single crowns. **Int J Prosthodont**, v. 26, n. 2, p. 151–160, 2013.

WENZEL, A, HIRSCH. E., CHRISTENSEN, J., MATZEN, L. H., SCAF, G., FRYDENBERG, M. Detection of cavitated approximal surfaces using cone beam CT and intraoral receptors. **Dentomaxillofac Radiol**, v. 42, n.1, 2013.

ANEXO A – Parecer do Comitê de Ética



PARECER CONSUBSTANCIADO DO CEP

DADOS DO PROJETO DE PESQUISA

Título da Pesquisa: Análise de artefatos metálicos gerados por diferentes materiais restauradores e sua influência na identificação de gaps em imagens de tomografia computadorizada de feixe cônico

Pesquisador: Karina Lopes Devito

Área Temática:

Versão: 1

CAAE: 80618217.6.0000.5147

Instituição Proponente: FACULDADE DE ODONTOLOGIA

Patrocinador Principal: Financiamento Próprio

DADOS DO PARECER

Número do Parecer: 2.435.835

Apresentação do Projeto:

Apresentação do projeto está clara, detalhada de forma objetiva, descreve as bases científicas que justificam o estudo, estando de acordo com as atribuições definidas na Resolução CNS 466/12 de 2012, item III.

Objetivo da Pesquisa:

Os Objetivos da pesquisa estão claros bem delineados, apresenta clareza e compatibilidade com a proposta, tendo adequação da metodologia aos objetivos pretendido, de acordo com as atribuições definidas na Norma Operacional CNS 001 de 2013, item 3.4.1 - 4.

Avaliação dos Riscos e Benefícios:

Riscos e benefícios descritos em conformidade com a natureza e propósitos da pesquisa. O risco que o projeto apresenta é caracterizado como risco mínimo e benefícios esperados estão adequadamente descritos. A avaliação dos Riscos e Benefícios está de acordo com as atribuições definidas na Resolução CNS 466/12 de 2012, itens III; III.2 e V.

Comentários e Considerações sobre a Pesquisa:

O projeto está bem estruturado, delineado e fundamentado, sustenta os objetivos do estudo em sua metodologia de forma clara e objetiva, e se apresenta em consonância com os princípios éticos norteadores da ética na pesquisa científica envolvendo seres humanos elencados na

Endereço: JOSE LOURENCO KELMER S/N
Bairro: SAO PEDRO **CEP:** 36.036-900
UF: MG **Município:** JUIZ DE FORA
Telefone: (32)2102-3788 **Fax:** (32)1102-3788 **E-mail:** cep.propesq@ufjf.edu.br

resolução 466/12 do CNS e com a Norma Operacional Nº 001/2013 CNS.

Considerações sobre os Termos de apresentação obrigatória:

O protocolo de pesquisa está em configuração adequada, apresenta FOLHA DE ROSTO devidamente preenchida, com o título em português, identifica o patrocinador pela pesquisa, estando de acordo com as atribuições definidas na Norma Operacional CNS 001 de 2013 item 3.3 letra a; e 3.4.1 item 16. Apresenta o TERMO DE CONSENTIMENTO LIVRE ESCLARECIDO em linguagem clara para compreensão dos participantes, apresenta justificativa e objetivo, campo para identificação do participante, descreve de forma suficiente os procedimentos, informa que uma das vias do TCLE será entregue aos participantes, assegura a liberdade do participante recusar ou retirar o consentimento sem penalidades, garante sigilo e anonimato, explicita riscos e desconfortos esperados, ressarcimento com as despesas, indenização diante de eventuais danos decorrentes da pesquisa, contato do pesquisador e do CEP e informa que os dados da pesquisa ficarão arquivados com o pesquisador pelo período de cinco anos, de acordo com as atribuições definidas na Resolução CNS 466 de 2012, itens: IV letra b; IV.3 letras a, b, d, e, f, g e h; IV. 5 letra d e XI.2 letra f. Apresenta o INSTRUMENTO DE COLETA DE DADOS de forma pertinente aos objetivos delineados e preserva os participantes da pesquisa. O Pesquisador apresenta titulação e experiência compatível com o projeto de pesquisa, estando de acordo com as atribuições definidas no Manual Operacional para CPEs. Apresenta DECLARAÇÃO de infraestrutura e de concordância com a realização da pesquisa de acordo com as atribuições definidas na Norma Operacional CNS 001 de 2013 item 3.3 letra h.

Conclusões ou Pendências e Lista de Inadequações:

Diante do exposto, o projeto está aprovado, pois está de acordo com os princípios éticos norteadores da ética em pesquisa estabelecido na Res. 466/12 CNS e com a Norma Operacional Nº 001/2013 CNS. Data prevista para o término da pesquisa: Janeiro de 2019.

Considerações Finais a critério do CEP:

Diante do exposto, o Comitê de Ética em Pesquisa CEP/UFJF, de acordo com as atribuições definidas na Res. CNS 466/12 e com a Norma Operacional Nº 001/2013 CNS, manifesta-se pela APROVAÇÃO do protocolo de pesquisa proposto. Vale lembrar ao pesquisador responsável pelo projeto, o compromisso de envio ao CEP de relatórios parciais e/ou total de sua pesquisa informando o andamento da mesma, comunicando também eventos adversos e eventuais

Endereço: JOSE LOURENCO KELMER S/N			
Bairro: SAO PEDRO			CEP: 36.036-900
UF: MG	Município: JUIZ DE FORA		
Telefone: (32)2102-3788	Fax: (32)1102-3788	E-mail: cep.propesq@ufjf.edu.br	

Este parecer foi elaborado baseado nos documentos abaixo relacionados:

Tipo Documento	Arquivo	Postagem	Autor	Situação
Informações Básicas do Projeto	PB_INFORMAÇÕES_BÁSICAS_DO_PROJETO_1037764.pdf	30/11/2017 22:01:46		Aceito
Outros	Lattes_Karina.pdf	30/11/2017 21:59:30	Karina Lopes Devito	Aceito
TCLE / Termos de Assentimento / Justificativa de Ausência	Dispensa_TCLE.pdf	30/11/2017 21:58:41	Karina Lopes Devito	Aceito
Declaração de Manuseio Material Biológico / Biorepositório / Biobanco	Declaracao_Banco_de_Dentes.pdf	30/11/2017 21:57:28	Karina Lopes Devito	Aceito
Declaração de Instituição e Infraestrutura	Declaracao_de_Infraestrutura.pdf	30/11/2017 21:57:04	Karina Lopes Devito	Aceito
Projeto Detalhado / Brochura Investigador	Projeto_CEP.pdf	30/11/2017 21:56:43	Karina Lopes Devito	Aceito
Folha de Rosto	folhaDeRosto.pdf	30/11/2017 21:54:58	Karina Lopes Devito	Aceito

Situação do Parecer:

Aprovado

Necessita Apreciação da CONEP:

Não

JUIZ DE FORA, 13 de Dezembro de 2017

ANEXO B – Normas para publicação



Clinical Oral Investigations

[Journal home](#) > [Submission guidelines](#)

Submission guidelines

Contents

- [Instructions for Authors](#)
 - [Types of papers](#)
 - [Editorial Procedure](#)
 - [Manuscript Submission](#)
 - [Title Page](#)
 - [Text](#)
 - [References](#)
 - [Tables](#)
 - [Artwork and Illustrations Guidelines](#)
 - [Electronic Supplementary Material](#)
 - [Clinical Trial Registration](#)
 - [English Language Editing](#)
 - [Ethical Responsibilities of Authors](#)
 - [Authorship principles](#)
 - [Compliance with Ethical Standards](#)
 - [Disclosure of potential conflicts of interest](#)
 - [Research involving human participants and/or animals](#)
 - [Informed consent](#)
 - [Research Data Policy](#)
 - [After Acceptance](#)
 - [Open Choice](#)

Instructions for Authors

Types of papers

Papers may be submitted for the following sections:

- Original articles
- Invited reviews
- Short communications – with up to 2000 words and up to two figures and/or tables
- Discussion paper
- Letters to the editor

It is the general policy of this journal not to accept case reports and pilot studies.

[Back to top ↑](#)

Editorial Procedure

If you have any questions please contact:

Professor Dr. M. Hannig

University Hospital of Saarland

Department of Parodontology and Conservative Dentistry

Building 73

66421 Homburg/Saar

Germany

Email: eic.hannig@uks.eu

[Back to top ↑](#)

Manuscript Submission

Manuscript Submission

Submission of a manuscript implies: that the work described has not been published before; that it is not under consideration for publication anywhere else; that its publication has been approved by all co-authors, if any, as well as by the responsible authorities – tacitly or explicitly – at the institute where the work has been carried out. The publisher will not be held legally responsible should there be any claims for compensation.

Permissions

Authors wishing to include figures, tables, or text passages that have already been published elsewhere are required to obtain permission from the copyright owner(s) for both the print and online format and to include evidence that such permission has been granted when submitting their papers. Any material received without such evidence will be assumed to originate from the authors.

Online Submission

Please follow the hyperlink "Submit online" on the right and upload all of your manuscript files following the instructions given on the screen.

Please ensure you provide all relevant editable source files. Failing to submit these source files might cause unnecessary delays in the review and production process.

Further Useful Information

please follow the link below

[Further Useful Information](#)

The Springer Author Academy is a set of comprehensive online training pages mainly geared towards first-time authors. At this point, more than 50 pages offer advice to authors on how to write and publish a journal article.

[Springer Author Academy](#)

[Back to top ↑](#)

Title Page

The title page should include:

- The name(s) of the author(s)
- A concise and informative title
- The affiliation(s) and address(es) of the author(s)
- The e-mail address, telephone and fax numbers of the corresponding author

Abstract

Please provide a structured abstract of 150 to 250 words which should be divided into the following sections:

- Objectives (stating the main purposes and research question)
- Materials and Methods
- Results
- Conclusions
- Clinical Relevance

These headings must appear in the abstract.

Keywords

Please provide 4 to 6 keywords which can be used for indexing purposes.

[Back to top ↑](#)

Text

Text Formatting

Manuscripts should be submitted in Word.

- Use a normal, plain font (e.g., 10-point Times Roman) for text.
- Use italics for emphasis.
- Use the automatic page numbering function to number the pages.
- Do not use field functions.
- Use tab stops or other commands for indents, not the space bar.
- Use the table function, not spreadsheets, to make tables.
- Use the equation editor or MathType for equations.
- Save your file in docx format (Word 2007 or higher) or doc format (older Word versions).

Manuscripts with mathematical content can also be submitted in LaTeX.

[LaTeX macro package \(Download zip, 188 kB\)](#) ↓

Headings

Please use no more than three levels of displayed headings.

Abbreviations

Abbreviations should be defined at first mention and used consistently thereafter.

Footnotes

Footnotes can be used to give additional information, which may include the citation of a reference included in the reference list. They should not consist solely of a reference citation, and they should never include the bibliographic details of a reference. They should also not contain any figures or tables.

Footnotes to the text are numbered consecutively; those to tables should be indicated by superscript lower-case letters (or asterisks for significance values and other statistical data). Footnotes to the title or the authors of the article are not given reference symbols.

Always use footnotes instead of endnotes.

Acknowledgments

Acknowledgments of people, grants, funds, etc. should be placed in a separate section on the title page. The names of funding organizations should be written in full.

[Back to top ↑](#)

References

Citation

Reference citations in the text should be identified by numbers in square brackets. Some examples:

1. Negotiation research spans many disciplines [3].
2. This result was later contradicted by Becker and Seligman [5].
3. This effect has been widely studied [1-3, 7].

Reference list

The list of references should only include works that are cited in the text and that have been published or accepted for publication. Personal communications and unpublished works should only be mentioned in the text. Do not use footnotes or endnotes as a substitute for a reference list.

The entries in the list should be numbered consecutively.

- Journal article
Gamelin FX, Baquet G, Berthoin S, Thevenet D, Nourry C, Nottin S, Bosquet L (2009) Effect of high intensity intermittent training on heart rate variability in prepubescent children. *Eur J Appl Physiol* 105:731-738. <https://doi.org/10.1007/s00421-008-0955-8>

Ideally, the names of all authors should be provided, but the usage of "et al" in long author lists will also be accepted:

Smith J, Jones M Jr, Houghton L et al (1999) Future of health insurance. *N Engl J Med* 341:325-329

- Article by DOI
Slifka MK, Whitton JL (2000) Clinical implications of dysregulated cytokine production. *J Mol Med*. <https://doi.org/10.1007/s001090000086>
- Book
South J, Blass B (2001) *The future of modern genomics*. Blackwell, London

- **Book chapter**
Brown B, Aaron M (2001) The politics of nature. In: Smith J (ed) The rise of modern genomics, 3rd edn. Wiley, New York, pp 230-257
- **Online document**
Cartwright J (2007) Big stars have weather too. IOP Publishing PhysicsWeb. <http://physicsweb.org/articles/news/11/6/16/1>. Accessed 26 June 2007
- **Dissertation**
Trent JW (1975) Experimental acute renal failure. Dissertation, University of California

Always use the standard abbreviation of a journal's name according to the ISSN List of Title Word Abbreviations, see

[ISSN.org LTWA](#)

If you are unsure, please use the full journal title.

For authors using EndNote, Springer provides an output style that supports the formatting of in-text citations and reference list.

[EndNote style \(Download zip, 4 kB\)](#) ↓

Authors preparing their manuscript in LaTeX can use the bibtex file `spbasic.bst` which is included in Springer's LaTeX macro package.

[Back to top](#) ↑

Tables


- All tables are to be numbered using Arabic numerals.
- Tables should always be cited in text in consecutive numerical order.
- For each table, please supply a table caption (title) explaining the components of the table.
- Identify any previously published material by giving the original source in the form of a reference at the end of the table caption.
- Footnotes to tables should be indicated by superscript lower-case letters (or asterisks for significance values and other statistical data) and included beneath the table body.

Artwork and Illustrations Guidelines

Electronic Figure Submission

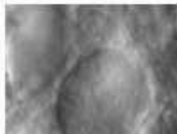- Supply all figures electronically.
- Indicate what graphics program was used to create the artwork.
- For vector graphics, the preferred format is EPS; for halftones, please use TIFF format. MSOffice files are also acceptable.
- Vector graphics containing fonts must have the fonts embedded in the files.
- Name your figure files with "Fig" and the figure number, e.g., Fig1.eps.

Line Art




- Definition: Black and white graphic with no shading.
- Do not use faint lines and/or lettering and check that all lines and lettering within the figures are legible at final size.
- All lines should be at least 0.1 mm (0.3 pt) wide.
- Scanned line drawings and line drawings in bitmap format should have a minimum resolution of 1200 dpi.
- Vector graphics containing fonts must have the fonts embedded in the files.

Halftone Art



- Definition: Photographs, drawings, or paintings with fine shading, etc.
- If any magnification is used in the photographs, indicate this by using scale bars within the figures themselves.
- Halftones should have a minimum resolution of 300 dpi.

Combination Art



- Definition: a combination of halftone and line art, e.g., halftones containing line drawing, extensive lettering, color diagrams, etc.
- Combination artwork should have a minimum resolution of 600 dpi.

Color Art

- Color art is free of charge for online publication.
- If black and white will be shown in the print version, make sure that the main information will still be visible. Many colors are not distinguishable from one another when converted to black and white. A simple way to check this is to make a xerographic copy to see if the necessary distinctions between the different colors are still apparent.
- If the figures will be printed in black and white, do not refer to color in the captions.
- Color illustrations should be submitted as RGB (8 bits per channel).

Figure Lettering

- To add lettering, it is best to use Helvetica or Arial (sans serif fonts).
- Keep lettering consistently sized throughout your final-sized artwork, usually about 2–3 mm (8–12 pt).
- Variance of type size within an illustration should be minimal, e.g., do not use 8-pt

- Do not include titles or captions within your illustrations.

Figure Numbering

- All figures are to be numbered using Arabic numerals.
- Figures should always be cited in text in consecutive numerical order.
- Figure parts should be denoted by lowercase letters (a, b, c, etc.).
- If an appendix appears in your article and it contains one or more figures, continue the consecutive numbering of the main text. Do not number the appendix figures, "A1, A2, A3, etc." Figures in online appendices (Electronic Supplementary Material) should, however, be numbered separately.

Figure Captions

- Each figure should have a concise caption describing accurately what the figure depicts. Include the captions in the text file of the manuscript, not in the figure file.
- Figure captions begin with the term **Fig.** in bold type, followed by the figure number, also in bold type.
- No punctuation is to be included after the number, nor is any punctuation to be placed at the end of the caption.
- Identify all elements found in the figure in the figure caption; and use boxes, circles, etc., as coordinate points in graphs.
- Identify previously published material by giving the original source in the form of a reference citation at the end of the figure caption.

Figure Placement and Size

- Figures should be submitted separately from the text, if possible.
- When preparing your figures, size figures to fit in the column width.
- For large-sized journals the figures should be 84 mm (for double-column text areas), or 174 mm (for single-column text areas) wide and not higher than 234 mm.
- For small-sized journals, the figures should be 119 mm wide and not higher than 195 mm.

Permissions

If you include figures that have already been published elsewhere, you must obtain permission from the copyright owner(s) for both the print and online format. Please be aware that some publishers do not grant electronic rights for free and that Springer will not be able to refund any costs that may have occurred to receive these permissions. In such cases, material from other sources should be used.

Accessibility

Accessibility

In order to give people of all abilities and disabilities access to the content of your figures, please make sure that

- All figures have descriptive captions (blind users could then use a text-to-speech software or a text-to-Braille hardware)
- Patterns are used instead of or in addition to colors for conveying information (colorblind users would then be able to distinguish the visual elements)
- Any figure lettering has a contrast ratio of at least 4.5:1

[Back to top ↑](#)

Electronic Supplementary Material

Springer accepts electronic multimedia files (animations, movies, audio, etc.) and other supplementary files to be published online along with an article or a book chapter. This feature can add dimension to the author's article, as certain information cannot be printed or is more convenient in electronic form.

Before submitting research datasets as electronic supplementary material, authors should read the journal's Research data policy. We encourage research data to be archived in data repositories wherever possible.

Submission

- Supply all supplementary material in standard file formats.
- Please include in each file the following information: article title, journal name, author names; affiliation and e-mail address of the corresponding author.
- To accommodate user downloads, please keep in mind that larger-sized files may require very long download times and that some users may experience other problems during downloading.

Audio, Video, and Animations

- Aspect ratio: 16:9 or 4:3
- Maximum file size: 25 GB
- Minimum video duration: 1 sec
- Supported file formats: avi, wmv, mp4, mov, m2p, mp2, mpg, mpeg, flv, mxf, mts,

- Supported file formats: avi, wmv, mp4, mov, m2p, mp2, mpg, mpeg, flv, mxf, mts, m4v, 3gp

Text and Presentations

- Submit your material in PDF format; .doc or .ppt files are not suitable for long-term viability.
- A collection of figures may also be combined in a PDF file.

Spreadsheets

- Spreadsheets should be submitted as .csv or .xlsx files (MS Excel).

Specialized Formats

- Specialized format such as .pdb (chemical), .vrl (VRML), .nb (Mathematica notebook), and .tex can also be supplied.

Collecting Multiple Files

- It is possible to collect multiple files in a .zip or .gz file.

Numbering

- If supplying any supplementary material, the text must make specific mention of the material as a citation, similar to that of figures and tables.
- Refer to the supplementary files as "Online Resource", e.g., "... as shown in the animation (Online Resource 3)", "... additional data are given in Online Resource 4".
- Name the files consecutively, e.g. "ESM_3.mpg", "ESM_4.pdf".

Captions

- For each supplementary material, please supply a concise caption describing the content of the file.

Processing of supplementary files

- Electronic supplementary material will be published as received from the author without any conversion, editing, or reformatting.

Accessibility

In order to give people of all abilities and disabilities access to the content of your supplementary files, please make sure that

- The manuscript contains a descriptive caption for each supplementary material
- Video files do not contain anything that flashes more than three times per second (so

Clinical Trial Registration

Clinical trials must be registered prior to submission of manuscripts. The registration site must be publicly available in English.

Recommended sites are: <https://www.isrctn.com> ; <https://www.clinicaltrialsregister.eu>; <https://clinicaltrials.gov> or similar.

The registration number is required for the submission and must appear on the title page.

[Back to top ↑](#)

English Language Editing

For editors and reviewers to accurately assess the work presented in your manuscript you need to ensure the English language is of sufficient quality to be understood. If you need help with writing in English you should consider:

- Asking a colleague who is a native English speaker to review your manuscript for clarity.
- Visiting the English language tutorial which covers the common mistakes when writing in English.
- Using a professional language editing service where editors will improve the English to ensure that your meaning is clear and identify problems that require your review. Two such services are provided by our affiliates Nature Research Editing Service and American Journal Experts. Springer authors are entitled to a 10% discount on their first submission to either of these services, simply follow the links below.

[English language tutorial](#)

[Nature Research Editing Service](#)

[American Journal Experts](#)

Please note that the use of a language editing service is not a requirement for publication in

Ethical Responsibilities of Authors

This journal is committed to upholding the integrity of the scientific record. As a member of the Committee on Publication Ethics (COPE) the journal will follow the COPE guidelines on how to deal with potential acts of misconduct.

Authors should refrain from misrepresenting research results which could damage the trust in the journal, the professionalism of scientific authorship, and ultimately the entire scientific endeavour. Maintaining integrity of the research and its presentation is helped by following the rules of good scientific practice, which include*:

- The manuscript should not be submitted to more than one journal for simultaneous consideration.
- The submitted work should be original and should not have been published elsewhere in any form or language (partially or in full), unless the new work concerns an expansion of previous work. (Please provide transparency on the re-use of material to avoid the concerns about text-recycling ('self-plagiarism').
- A single study should not be split up into several parts to increase the quantity of submissions and submitted to various journals or to one journal over time (i.e. 'salami-slicing/publishing').
- Concurrent or secondary publication is sometimes justifiable, provided certain conditions are met. Examples include: translations or a manuscript that is intended for a different group of readers.
- Results should be presented clearly, honestly, and without fabrication, falsification or inappropriate data manipulation (including image based manipulation). Authors should adhere to discipline-specific rules for acquiring, selecting and processing data.
- No data, text, or theories by others are presented as if they were the author's own ('plagiarism'). Proper acknowledgements to other works must be given (this includes material that is closely copied (near verbatim), summarized and/or paraphrased), quotation marks (to indicate words taken from another source) are used for verbatim copying of material, and permissions secured for material that is copyrighted.

Important note: the journal may use software to screen for plagiarism.

- Authors should make sure they have permissions for the use of software, questionnaires/(web) surveys and scales in their studies (if appropriate).
- Authors should avoid untrue statements about an entity (who can be an individual person or a company) or descriptions of their behavior or actions that could potentially be seen as personal attacks or allegations about that person.
- Research that may be misapplied to pose a threat to public health or national security should be clearly identified in the manuscript (e.g. dual use of research). Examples include creation of harmful consequences of biological agents or toxins, disruption of immunity of vaccines, unusual hazards in the use of chemicals, weaponization of research/technology (amongst others).
- Authors are strongly advised to ensure the author group, the Corresponding Author, and the order of authors are all correct at submission. Adding and/or deleting authors during the revision stages is generally not permitted, but in some cases may be warranted. Reasons for changes in authorship should be explained in detail. Please note that changes to authorship cannot be made after acceptance of a manuscript.

*All of the above are guidelines and authors need to make sure to respect third parties rights such as copyright and/or moral rights.

Upon request authors should be prepared to send relevant documentation or data in order to verify the validity of the results presented. This could be in the form of raw data, samples, records, etc. Sensitive information in the form of confidential or proprietary data is excluded.

If there is suspicion of misbehavior or alleged fraud the Journal and/or Publisher will carry out an investigation following COPE guidelines. If, after investigation, there are valid concerns, the author(s) concerned will be contacted under their given e-mail address and given an opportunity to address the issue. Depending on the situation, this may result in the Journal's and/or Publisher's implementation of the following measures, including, but not limited to:

- If the manuscript is still under consideration, it may be rejected and returned to the author.
- If the article has already been published online, depending on the nature and severity of the infraction:

- If the manuscript is still under consideration, it may be rejected and returned to the author.
- If the article has already been published online, depending on the nature and severity of the infraction:
 - an erratum/correction may be placed with the article
 - an expression of concern may be placed with the article
 - or in severe cases retraction of the article may occur.

The reason will be given in the published erratum/correction, expression of concern or retraction note. Please note that retraction means that the article is **maintained on the platform**, watermarked "retracted" and the explanation for the retraction is provided in a note linked to the watermarked article.

- The author's institution may be informed
- A notice of suspected transgression of ethical standards in the peer review system may be included as part of the author's and article's bibliographic record.

Fundamental errors

Authors have an obligation to correct mistakes once they discover a significant error or inaccuracy in their published article. The author(s) is/are requested to contact the journal and explain in what sense the error is impacting the article. A decision on how to correct the literature will depend on the nature of the error. This may be a correction or retraction. The retraction note should provide transparency which parts of the article are impacted by the error.

Suggesting / excluding reviewers

Authors are welcome to suggest suitable reviewers and/or request the exclusion of certain individuals when they submit their manuscripts. When suggesting reviewers, authors should make sure they are totally independent and not connected to the work in any way. It is strongly recommended to suggest a mix of reviewers from different countries and different institutions. When suggesting reviewers, the Corresponding Author must provide an institutional email address for each suggested reviewer, or, if this is not possible to include other means of verifying the identity such as a link to a personal homepage, a link to the publication record or a researcher or author ID in the submission letter. Please note that the Journal may not use the suggestions, but suggestions are appreciated and may

ANEXO C – COMPROVANTE DE SUBMISSÃO

Clinical Oral Investigations - Submission Notification to co-author



Traduzir a mensagem para: Português | Nunca traduzir do: Inglês



Clinical Oral Investigations <em@editorialmanager.com>

Dom, 27/10/2019 17:45

Você



Re: "Influence of artifacts on identifying gaps in indirect restorations evaluated in cone beam computed tomography images"

Full author list: Letícia Mauad; Karolina Fardim; Alessiana Machado; Paulo Victor Doriguêto; Daniela Almeida; Karina Lopes Devito, Ph.D

Dear Miss Letícia Mauad,

We have received the submission entitled: "Influence of artifacts on identifying gaps in indirect restorations evaluated in cone beam computed tomography images" for possible publication in Clinical Oral Investigations, and you are listed as one of the co-authors.

The manuscript has been submitted to the journal by Dr. Dra Karina Lopes Devito who will be able to track the status of the paper through his/her login.

If you have any objections, please contact the editorial office as soon as possible. If we do not hear back from you, we will assume you agree with your co-authorship.

Thank you very much.

With kind regards,